ELSEVIER
SAUNDERS

Anesthesiology Clin
25 (2007) 511–533

ANESTHESIOLOGY
CLINICS

Considerations for Airway Management for Cervical Spine Surgery in Adults

Edward T. Crosby, MD, FRCPC

Department of Anesthesiology, University of Ottawa, The Ottawa Hospital–General Campus, Suite 1401, 501 Smyth Road, Ottawa, Ontario K1H 8L6, Canada

Surgery on the cervical spine runs the gamut from minor interventions done in a minimally invasive fashion on a short-stay or ambulatory basis, to major surgical undertakings of a high-risk, high-threat nature done to stabilize a degraded skeletal structure to preserve and protect neural elements. Planning for optimum airway management and anesthesia care is facilitated by an appreciation of the disease processes that affect the cervical spine and their biomechanical implications and an understanding of the imaging and operative techniques used to evaluate and treat these conditions. This article provides some of the background information and evidence to allow the anesthesia practitioner to develop a conceptual framework within which to develop strategies for care when a patient is presented for surgery on the cervical spine.

The adult cervical spine: anatomy and stability

Anatomy of the cervical spine

The first cervical vertebra, the atlas, is a ring-shaped structure with thick anterior and posterior arches that merge with large lateral masses (Fig. 1). Large kidney-shaped depressions on the upper aspects of the lateral masses articulate with the occipital condyles of the skull. The flatter interior surfaces of the lateral masses transmit the weight of the skull onto the superior facet joints of the axis, the second cervical vertebra. The body of the axis extends upward to form the odontoid process; the narrowed waist of the odontoid process is tethered posteriorly by the transverse ligament. Alar and apical ligaments fan upward from the odontoid process to insert on the anterior margins of the foramen magnum of the skull.

E-mail address: ecrosby@sympatico.ca

doi:10.1016/j.anclin.2007.05.001 *anesthesiology.theclinics.com*

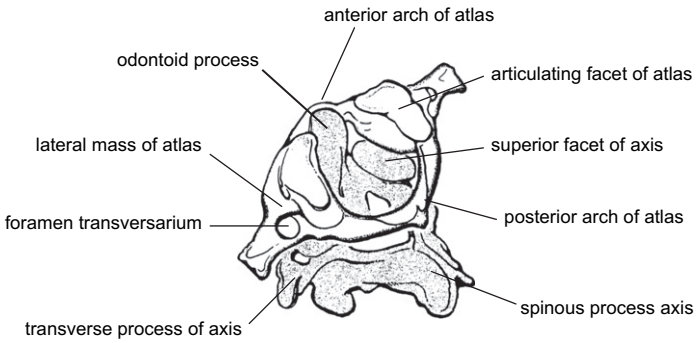

Fig. 1. Detail of atlantoaxial (C1-C2) articulation with skull removed.

The subaxial cervical vertebrae from C3 to C5 are anatomically more typical vertebra. There is an intervertebral disk between C2 and C3 and each subjacent pair of vertebra, and these disks account for about 25% of total spinal length at maturity. The disks are composed of peripheral fibrocartilage, the annulus fibrosis, surrounding a soft central core, the nucleus pulposus. The nucleus contains a high proportion of hydrophilic glycosaminoglycans and functions as a cushion. The arches of the subaxial cervical vertebrae articulate with each other by horizontally oriented facet joints.

The anterior longitudinal ligament ascends along the anterior surface of the spine. It terminates over the anterior arch of the atlas inserting on the base of the skull. The posterior longitudinal ligament courses upward along the dorsal surface of the vertebral bodies, fans over the body of the axis and odontoid process, and terminates as a tectorial membrane, which also inserts into the skull. The ligamentum flavum connects the adjacent lamina; it is often a tenuous structure in the cervical spine. Coursing between spinous processes are the interspinous and supraspinous ligaments.

Anatomy of the aging spine

The aging spine undergoes considerable changes in anatomy [1]. The quantity of water present in the disk nucleus decreases and both spinal height and the cushioning effect previously described are reduced. Gaps and fissures may develop in the disks, and with time they may become desiccated and even ossified. As the spine decreases in length, there may be buckling of both anterior and posterior longitudinal ligaments. The buckling posterior ligament may project into the spinal canal, reducing the space available for the cord. Bony osteophytes and excrescences may develop in the region of the vertebral bodies; end plate osteophytes may grow across the disk spaces and merge with osteophytes of subjacent vertebra to form bridging osteophytes. If these bridging osteophytes involve the posterior end plates, they may also project into the spinal canal, narrowing the lumen.

Patients with congenitally narrow spinal canals are at greater risk for spinal cord compression as a result of these pathologic changes. Large bridging osteophytes on the anterior end plates may result in dysphagia, respiratory symptoms, or may lead to difficulties with airway management. The aperture of the foramen, which transmit the spinal nerves, may be reduced both with the loss of spinal length and ossification of these soft tissues around the vertebral column. These age-related changes account for the symptomatology in most patients presenting for cervical spine surgery.

Movement and stability of the cervical spine

Flexion-extension occurs in the upper cervical spine at both the atlanto-occipital and atlantoaxial articulations and a combined 24 degrees of motion may be achieved [2]. For the jaw to open wide, head extension must simultaneously occur [3]. Extension probably facilitates mouth opening by stretching the neck muscles responsible for jaw gape, allowing them to shorten by greater absolute lengths and increasing mouth opening. Head extension decreases the Mallampati class by an average of 0.5 for classes 2, 3, and 4 compared with when the examination is made with the head in a neutral position [4]. Significantly reduced extension limits mouth opening and Calder and colleagues [5] have reported that limited separation of the upper posterior spinal elements reduces both head extension and mouth opening resulting in more difficult direct laryngoscopy.

The ligaments contributing to the stability of the upper complex are the transverse, apical, and alar ligaments and the superior terminations of the anterior and posterior longitudinal ligaments. In adults, the transverse ligament limits separation of the odontoid process (dens) and the anterior arch of the atlas to less than or equal to 3 mm; this gap is termed the ''anterior atlas-dens interval.'' Destruction of these ligaments is a common consequence of severe and long-standing rheumatoid arthritis and is also seen commonly in Down syndrome [6]. The interval between the posterior aspect of the odontoid process and the anterior aspect of the posterior ring of the atlas is termed the ''posterior atlas-dens interval'' and is also referred to as the ''space available for the cord.'' A reduced posterior atlas-dens interval has been identified as being more predictive of increased potential for neurologic compromise than is an increased anterior atlas-dens interval [7]. The space available for the cord at C1 may be divided into one-half cord and one-half ''space''; the space allows for some encroachment of the spinal lumen without cord compromise (Fig. 2). Progressive narrowing of the canal combined with widening of the cord diameter reduces the space available for the cord between the C4 and C7 levels such that at the lower levels, the spinal cord normally fills approximately 75% of the cross-sectional area of the canal [8].

In adults, the dimensions of the midcervical spinal cord remain relatively constant with the average midsagittal cord diameter being 8 to 9 mm but the vertebral canal at the same levels shows substantial individual variation [9].

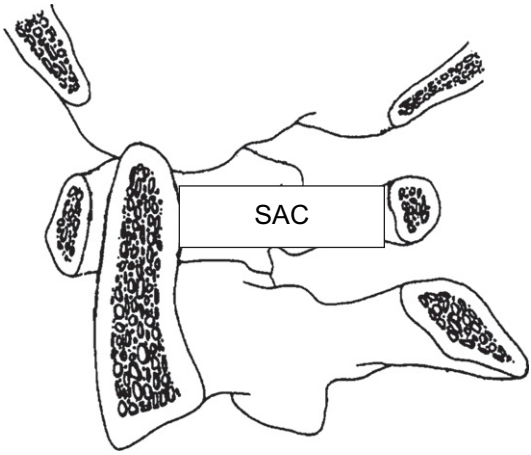

Fig. 2. Space available for the cord (SAC) at the C1 level. The odontoid process occupies about one third of the potential space, the spinal cord about one third, and the remainder is available as reserve; two thirds of the lumen is considered as SAC.

The canal is considered stenotic when its midsagittal dimension is less than 13 mm on a lateral radiograph or when the Torg-Pavlov ratio (calculated by comparing the sagittal diameter of the spinal canal with that of the corresponding vertebral body) is less than 0.8 [10]. A congenitally narrowed canal is hypothesized to increase the threat to the spinal cord with both acquired stenosis and following traumatic injury and is also an associated factor in transient cervical cord neuropraxia after injury [11].

A further 66 degrees of flexion-extension may be achieved in the lower cervical spine with the C5 to C7 segments contributing the largest component. There is an inverse relationship between age and range of motion (ie, as age increases, mobility decreases).

Biomechanics of the spinal cord and canal

For proper functioning of the spinal cord, a minimum canal lumen is required, both at rest and during movement, and cord compromise results if the canal space is less than that required; neurologic injury occurs if this reduction is persistent. The injury results from sustained mechanical pressure on the cord leading to both anatomic deformation and ischemia. Although neurologic deficits do not directly correlate with the degree of posttraumatic canal reduction, canal impingement is more commonly observed in patients with both spinal injury and neurologic deficit than in patients who do not have a deficit after spinal injury [12].

As the spine flexes, the posterior spinal elements, including the canal, transcribe an arc, but that of a larger circle than the anterior elements and the canal axially lengthens [13,14]. As it lengthens, its cross-sectional

area is reduced, and as it shortens (in extension), its area is increased; this behavior is termed the "Poisson effect." With flexion, the cord is stretched and its diameter is also reduced and the converse effect occurs in extension. The shortening and folding of the cord when the spine is in extension may result in a relative increase in the ratio of cord size to canal lumen, despite the potential increase in the lumen. Posterior protrusion of the disk annulus and buckling of the ligamentum flavum occurs in extension, which may further reduce canal dimensions at any given level. A number of age-related pathologic processes, including osteophyte formation and ossification of the posterior longitudinal ligament, may lead to further impingement on the canal lumen; these typically manifest a greater impact during spinal extension and may result in canal occlusion (Fig. 3) [15]. The cord tolerates a degree of elastic deformation while still maintaining normal neurologic function [16]. It may be further stretched and deformed, however, if there is a local anomaly, such as an osteophyte, prolapsed disk, or subluxed vertebral body projecting into the canal. These deformations may, over time, result in the application of strain and shear forces to the cord and ultimately result in myelopathy [15].

Prone positioning is often associated with modest degrees of extension, and there is evidence that canal stenosis is increased in patients with cervical myelopathy who are positioned prone [17]. Again, this is likely a manifestation of the soft tissue encroachment on the spinal canal with extension and aggravated by the pre-existent canal compromise. The clinical relevance of these findings is that a persistent malposition of an abnormal neck may result in a degree of cord compression. If the abnormality is modest, it is likely that the malposition needs to be of greater magnitude and persistent

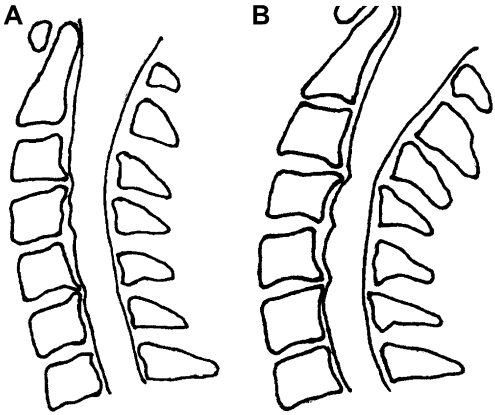

Fig. 3. Impact of extension on age-related changes. Posterior bridging osteophytes are diagrammed at the C3-C4 and C5-C6 levels and a buckling of the posterior longtitudinal ligament is shown at C4-C5 (*A*). With extension demonstrated in (*B*), the canal is shortened and the impact of the posterior changes on the lumenal space is increased; cord compression may occur or be aggravated.

to cause harm; as the anatomic derangement is increased, the duration of positional stress required to cause harm is shortened [18,19]. Prone positioning is also associated with increases in vena caval pressures, which may further reduce cord blood flow already compromised by cord compression by increasing resistance in the venous outflow channels [20].

Syndromes and disorders associated with cervical spinal pathology

Congenital syndromes with spinal pathology

The Chiari malformation is a congenital anomaly characterized by crowding of the posterior fossa by the neural elements and hindbrain herniation through the foramen magnum (Fig. 4) [21]. There is typically abnormal flow of cerebrospinal fluid across the foramen magnum and this may lead to the development of syringomyelia in the cervical cord. There are four types of the Chiari malformation described, and type I is the most common in adults, occurring in up to 0.5% of the population (Table 1) [21]. Type II malformations are more severe and associated with a myelomeningocele, and types III and IV are associated with high early mortality. Anomalies of the base of the skull and upper cervical spine are seen in many patients with type I and may include occipitalization of C1, fusion of C1 to C2, Klippel-Feil deformity, or cervical spina bifida occulta [22].

Although type I defects can be asymptomatic, patients may present with head and neck pain; occipital headache; gait disturbances; neurologic deficits of the upper extremities; and visual, co-ordination, and balance problems. The symptoms are thought to be related to either compression of the neural elements of the posterior fossa or spinal cord dysfunction

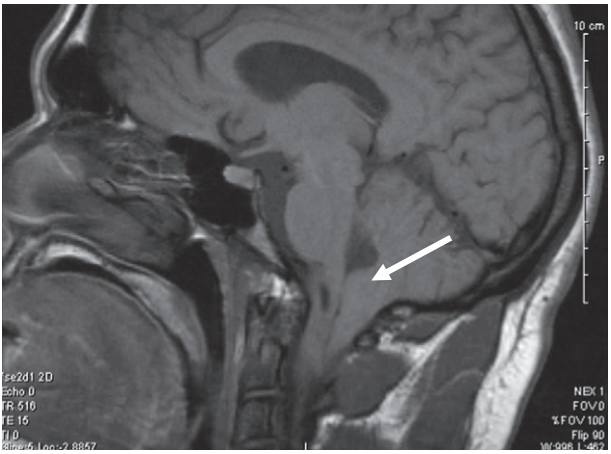

Fig. 4. Chiari type I malformation. Herniation of the cerebellar tonsils through the foramen magnum (*arrow*); crowding of the posterior fossa is also evident. This patient presented for suboccipital craniectomy.

Table 1
Chiari malformation types

Type	Characteristics
I	Displacement of cerebellar tonsils, crowding of posterior fossa, syringomyelia
II	Associated with myelomeningocele, displacement of medulla, fourth ventricle and cerebellum, elongation of pons and fourth ventricle, hydrocephalus common
III	Occipitocervical dysraphism with herniation of posterior fossa and brainstem
IV	Failed development of posterior fossa, malformations of brain and brainstem

related to the syrinx. In symptomatic patients, local decompression of the malformation, achieved by a suboccipital craniectomy, may relieve symptoms; more aggressive decompression with resection of cerebellar tissue and drainage of the syrinx with a syringosubarachnoid shunt may be necessary in some patients to provide relief.

Klippel-Feil syndrome is defined as a congenital fusion of two or more cervical vertebrae and three subtypes are described (Fig. 5, Table 2) [23]. Coexisting congenital defects of the spinal cord or brain are encountered in about a third of patients, consisting most commonly of cervical cord dysraphism or diastematomyelia and Chiari I malformations [24]. Although fused segments may directly limit the range of motion of the neck, more serious

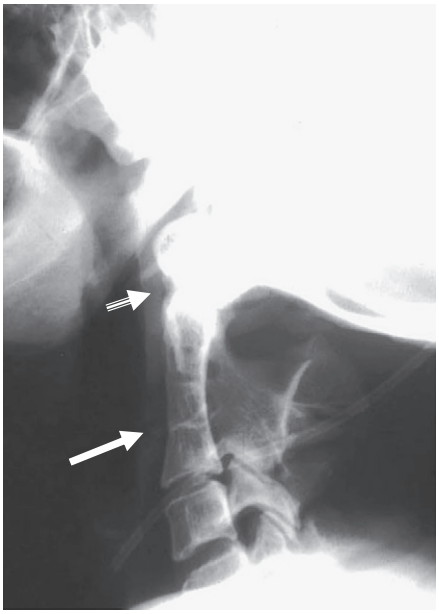

Fig. 5. Klippel-Feil syndrome type 1. Fused element comprising a number of contiguous vertebrae (*large arrow*); hypermobile C1-C2 articulation caused by the failed ossification of the tip of the odontoid process (*small arrow*).

Table 2
Klippel-Feil syndrome subtypes

Type	Characteristics
1	Cervical and upper thoracic fusion, typically of three or more levels
2	Multiple noncontiguous cervical fusions, associated hemivertebrae or atlanto-occipital fusion
3	Multiple contiguous, congenitally fused cervical segments

complications including instability, hypermobility, and symptomatic stenosis arise at the interspaces between fused segments [25]. Patients with progressive symptomatic segmental instability or neurologic compromise are candidates for surgical stabilization of the abnormal region of the cervical spine.

Inflammatory arthropathy and the cervical spine

Diffuse idiopathic skeletal hyperostosis is an ossifying disorder leading to new bone formation in spinal and extraspinal sites, paravertebral osteophyte formation, and ligamentous calcification with ossification (Fig. 6) [26]. The thoracolumbar spine is more frequently involved, although isolated or predominant cervical spine involvement is reported. Cervical spine involvement

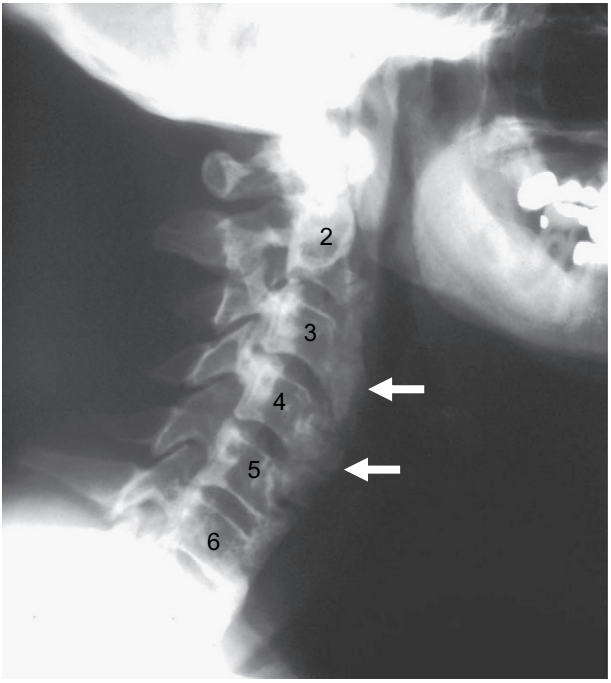

Fig. 6. Diffuse idiopathic skeletal hyperostosis (DISH). Multiple large anterior osteophytes characteristic of DISH (*arrows*).

in diffuse idiopathic skeletal hyperostosis is a recognized cause of various clinical manifestations involving the pharynx, larynx, and the esophagus resulting in such symptoms as dysphagia and airway symptoms, such as dyspnea or stridor; complications with endoscopy and intubation difficulties may also occur [26–28]. In patients with severe diffuse idiopathic skeletal hyperostosis, fractures of the cervical spine [29] may occur through the cervical body, and subsequent motion concentrates at the fracture site often leading to hematoma and cord compression; catastrophic neurologic sequelae may occur even after relatively minor trauma. Reduction and immobilization or instrumentation is advocated to restore spinal alignment and prevent neurologic injury.

Cervical spine involvement occurs in over half of patients with rheumatoid arthritis, usually in patients with severe, long-standing disease [6]. The most common abnormality is atlantoaxial subluxation, followed by atlanto-occipital arthritis with cranial settling and by lesions of the lower cervical spine [30]. Anterior atlantoaxial subluxation is the most prevalent form, accounting for about 80% of all types of subluxation. Vertical subluxation describes the upward migration of the odontoid process into the foramen magnum and results in inevitable neurologic compromise with myelopathy (Fig. 7). A large percentage of rheumatoid patients with cervical spine involvement progress toward complex instability patterns, including subaxial stepladder deformity, resulting in significant morbidity and

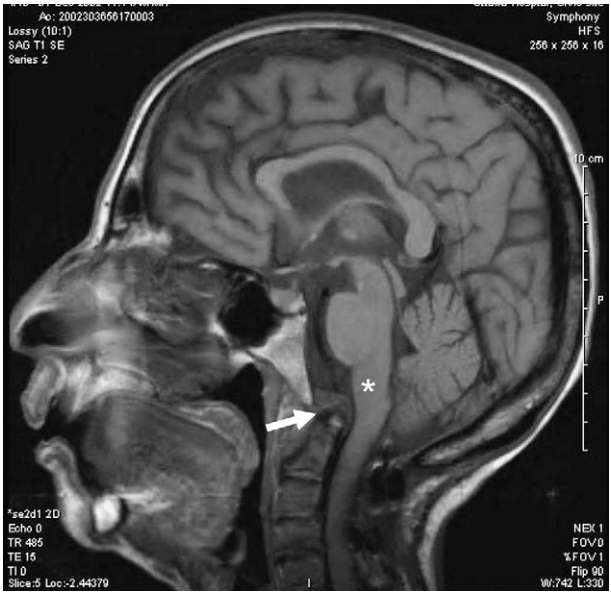

Fig. 7. Rheumatoid arthritis with vertical subluxation. Vertical subluxation of the odontoid process into the foramen magnum (*arrow*). There is considerable pannus surrounding the odontoid and the brainstem is elevated and compressed by the odontoid-pannus complex (*asterisk*).

mortality [31,32]. Once myelopathy occurs, the prognosis for neurologic recovery and long-term survival is poor. Surgery is indicated in patients with intractable pain and in those with progressive neurologic impairment and typically involves instrumentation and fusion.

Ankylosing spondylitis is a systemic inflammatory, progressive arthritic condition [33]. It mainly affects the sacroiliac joints and spine, and is characterized by inflammation or ossification of the disk, ligamentous structures, and facet joints (Fig. 8). With progression of the disease the spine frequently adopts a rigid fused kyphotic deformity. Atlantoaxial subluxation also occurs in up to 21% of patients with ankylosing spondylitis and may reflect a tendency toward hypermobility in spinal segments adjacent to fused elements. In advanced disease, a fixed cervical kyphosis may develop leading to a chin-on-chest deformity. The deformity prevents horizontal gaze; impedes activities of daily living, such as eating and drinking; and may induce severe pain. Cervicothoracic extension osteotomy with instrumentation (posterior or combined anterior and posterior) may be undertaken to return the spine to a more functional alignment [34].

Osteoporosis weakens the brittle ankylosing spondylitis spine and it is susceptible to fractures with minor or unrecognized trauma; they occur mainly in the lower cervical spine and are often displaced and unstable. Failure to immobilize the fracture may result in continuing movement at the fracture site, leading to a neurologic injury or rupture of the epidural veins

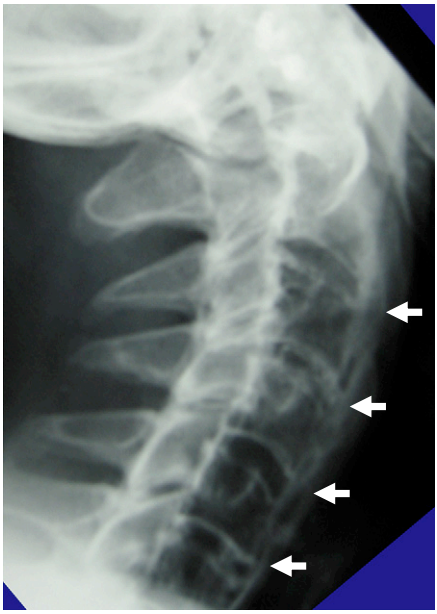

Fig. 8. Ankylosing spondylitis. Ossified anterior longitudinal ligament (*arrows*). Ossification of the posterior ligament is evident, and the vertebral bodies are significantly osteoporotic.

producing an epidural hematoma and subsequent cord compromise. A high rate of spinal cord injury is associated and mortality rates of 35% to 50% are associated with such fractures [35]. The onset of neurologic dysfunction may be delayed for weeks after the initial trauma [32]. In the presence of an unstable fracture, decompression and stabilization using internal fixation and bone graft, with or without laminectomy, is indicated.

Spondylomyelopathy and radiculopathy

The most common cause of radiculopathy is foraminal stenosis with encroachment of the spinal nerves primarily caused by decreased disk height and degenerative changes of the vertebral joints [36]. The final common pathway for cervical myelopathy is a decreased space available for the cord leading to spinal cord compression [37]. Many patients with cervical spondylotic myelopathy from purely degenerative changes also have some degree of congenital spinal stenosis. The age-related degenerative changes seen throughout the spine are the predominant pathology in cervical spondylotic myelopathy. Spinal cord compression resulting from these age-related degenerative changes is typically a slowly progressive process [38]. Cervical kyphosis is also common in patients with significant spondylotic changes, and this deformity aggravates the degree of compression as the spinal cord is stretched over the posterior aspects of the disks and vertebral bodies. Dynamic cord compression may occur with either extension or flexion in patients with severely compromised canal lumens [39]. Patients with chronic cervical spondylosis who suffer acute minor trauma, particularly a hyperextension injury, may sustain an acute spinal cord injury of varying severity superimposed on the long-standing myelopathy. Typically, this presents as a central cord syndrome with greater weakness in the upper extremities than in the lower extremities, and proximal rather than distal muscle involvement in each extremity.

For patients with foraminal stenosis and nerve compression or canal stenosis with cord compression and myelopathy, surgical decompression is indicated to alter the natural history of inevitable deterioration. Surgery can be expected to reduce pain and to slow or halt the progression of neurologic dysfunction, and may improve motor, sensory, and gait disturbances.

Cancer and metastasis to the cervical spine

The most common site of metastatic spread of tumors to the skeletal system occurs within the spine and metastatic tumors are the most frequent tumor involving the spinal column [40,41]. Metastases are more likely to be located within with the thoracic or lumbar regions than in the cervical spine; in particular, C1 and C2 are uncommonly involved. The tumors most likely to metastasize to the spine include lung, breast, prostate, and renal cell. The usual route of spread is hematogenous dissemination to the vertebral body with erosion back through the pedicles and extension into the epidural

space; most lesions remain extradural [42]. Collapse of the vertebral body may occur and neurologic dysfunction may result either from the deformity or by invasion of the canal by tumor or bone. Patients with spinal metastases typically complain of pain but less commonly manifest signs and symptoms of nerve root or cord compression. Pain is initially localized but may be aggravated by movement and alleviated by immobility if instability develops. The average survival time is greater than 1 year if all metastatic spinal tumors are considered and ranges from 7 to 9 months with lung tumors to 30 months with breast carcinoma. Indications for surgery include spinal instability resulting from progressive deformity, progressive neurologic deficit, and intractable pain; the goal of surgery is to provide for pain palliation and maintain ambulatory status, and about half the patients are still alive 1 year after operation [43]. Because most lesions originate in the vertebral body, an anterior approach with corpectomy offers the most direct approach for tumor excision, canal decompression, and reconstruction of the load-bearing column; the intent is to decompress the canal at the site of the metastasis and to stabilize the spine across the involved segments [44]. Supplemental posterior instrumentation may be used if there is gross vertebral instability, a kyphotic deformity, or if the cervicothoracic junction is involved.

Cervical spine trauma

The incidence of cervical spine injuries in victims of blunt trauma is 1.8% [45,46]. There is a higher incidence of cervical injury in patients who have experienced head trauma, especially among those with severe injury as determined by a low Glasgow Coma Score [47–49]. Most patients with cervical spine injuries have stable injuries. The finding of a focal neurologic deficit has also been identified as an important clinical finding predicting spinal injury [50]. Most patients with cervical spine injuries also have other injuries; in only 20% of instances are traumatic injuries restricted to the cervical spine [51]. Missed or delayed diagnosis of cervical spine injuries is associated with a high incidence of secondary neurologic injury, and there is a clinical imperative to recognize unstable injury at the outset [52–54]. There is a consensus at this time that high-risk patients should be screened with a three-view series with CT of areas of concern; spiral CT has also been used to assess high-risk patients and the results are similar to those of the three-view plus CT method [55–58].

An unusual pattern of delayed secondary cervical cord injury has been described in spine-injured patients and is now named "subacute progressive ascending myelopathy" [59–61]. This syndrome typically occurs in patients with a serious cord injury at a lower spinal level who experience an ascending pattern of secondary injury involving multiple segments remote from the initial level after an uneventful early clinical course. T2-weighted MRI reveals a high signal intensity located centrally within the cord and extending

rostral from the site of injury. Often no etiologic factors are identified and subacute progressive ascending myelopathy has been attributed to vascular perturbations (arterial hypotension or venous hypertension) or cord edema and inflammation.

Clinical management of the patient for cervical spine surgery

Diagnostic imaging of the cervical spine

Modern diagnostic imaging techniques are indispensable in the assessment and management of patients with cervical spinal or cord pathology and are used to diagnose and stage disorders, to facilitate treatment planning, and to evaluate the effect of treatment given.

Plain cervical radiography provides excellent screening imaging to assess bony anatomic characteristics and relationships and reveals many spinal pathologies and injuries. Unfortunately, not all injuries are revealed even with adequate plain imaging and a number of pathologic processes must be well advanced (eg, spinal metastasis) before they can be reliably detected. Both the occipitoatlantoaxial complex and the cervicothoracic junction may be difficult to assess with plain radiography; neural elements are poorly or not at all visualized. Tomograms may provide detailed assessments of osseous anatomy and relationships but are uncommonly used when CT is available. Myelography had been the gold standard for evaluating suspected cord compression but its status has been largely supplanted by MRI; it may still be useful if MRI is unavailable, contraindicated, or cannot be tolerated by the patient.

CT scanning provides detailed imaging of the osseous spinal axis and can be used either to evaluate areas of concern on plain radiography or as a primary imaging technique [62]. It provides useful information as to the degree of bony involvement by pathologic processes and can be used to assess both foraminal or canal compromise. Although it is not as useful to assess soft tissues and neural elements as is MRI, when combined with myelography, it can provide detailed assessment of the spinal axis.

MRI provides superb visualization of the neural elements and very good images of the osseous elements [63]. By varying the imaging techniques, various elements and pathologic states may be more critically evaluated. For example, T1 pulse sequences reveal the best anatomic detail, superior spatial resolution, and a good survey of marrow cavity (for assessing marrow replacement processes, such as metastasis), but demonstrate other pathologies poorly. T2 and fat-suppressed T2 images are very sensitive to pathologic changes in the neural and osseous elements and the paraspinal tissues and are superb for discriminating myelopathic changes in the cord. MRI can also be used to assess cerebrospinal fluid flow patterns to determine the patency of cerebrospinal fluid spaces and channels. Gadolinium enhancement increases the sensitivity of MRI investigations when used to evaluate disease processes that create enhancing lesions, such as metastatic cancer.

Surgery of the cervical spine: general principles

Generally speaking, surgeries on the cervical spine fall into one of two broad categories: decompression and fusion. Decompression of the canal or nerve foramen serves to provide greater functional space to the neural elements. The decompression may be limited or extensive, and more extensive decompressive operations tend to include fusion and immobilization. Simple decompression of the nerve foramen in the cervical region is typically done by diskectomy by way of an anterolateral approach, with the patient in the supine position. Small grafts, commonly anterior iliac crest bone or substitutes, are used to maintain anatomic relationships after diskectomy; placement of these grafts is facilitated by the use of small retractors used to spread the adjacent vertebral bodies.

Decompression of the canal is commonly done by a posterior approach with the patient in a prone position and the head fixed with surgical calipers. Most patients with cervical spondylosis and certainly those with ossification of the posterior longitudinal ligament have predominantly anterior compression of the cervical cord. Any posterior decompression procedure is an indirect technique that requires posterior shifting of the cord in the thecal sac to diminish the effect of the anterior compression. For this to occur, the preoperative sagittal alignment of the cervical spine must be at least straight and ideally lordotic. A kyphotic spine is less likely to allow sufficient posterior translation of the spinal cord to diminish symptoms. Multilevel anterior decompressions are indicated when the alignment of the cervical spine is kyphotic or when anterior bone elements are displaced into the canal compromising the lumen and they are also used in the surgical management of spinal metastases. Again, these procedures are done with the patient in a supine position and the head is typically fixed with surgical calipers.

The second broad category of cervical spine surgery is that of fusion and instrumentation. These operations may be combined with decompressive procedures to provide stability to a spine when the native stability has been compromised by the decompressive procedure or osteotomy (eg, ankylosing spondylitis) or may be done primarily to treat a spine rendered unstable by disease or injury. They may involve either an anterior or posterior approach. Modern instrumentation is typically segmental and the principal is to anchor the instrumentation to the stable segments adjacent to the injured or unstable segment and bridge the injury [64].

Airway management for cervical spine surgery

Patients with disorders of the cervical spine have a higher incidence of difficult intubation than is anticipated compared with matched controls, and the likelihood of these difficulties increases in patients with severe limitations of spinal movement [5]. In most patients presenting for limited procedures (eg, single level anterior discectomy) and in those patients with

well-preserved spinal range of motion, however, the incidence of difficulties with airway management approach that of normal controls.

Patients with disease processes resulting in atlantoaxial instability require special consideration for airway management. When a patient with atlantoaxial instability is laying supine, passive movement of the head with either flexion or extension may result in separation of the atlas and the axis resulting in increased subluxation. In particular, the sniffing position may significantly increase subluxation [65]. Providing support of the upper cervical spine to affected patients while they are in the supine position shifts the odontoid process forward, closing the anterior atlas-dens interval and increasing the posterior atlas-dens interval [65]. This positioning may be achieved with the use of a small flat pillow on which is placed a doughnut-shaped pillow. Care should be taken to minimize movement during airway interventions in these patients; consideration should be given to awake intubation in severely affected patients.

All airway maneuvers result in some degree of neck movement, both in general and specifically at the sites of injury or instability [66,67]. The amounts of movement are small, typically well within physiologic ranges, and their impact on secondary neurologic injury has not been defined. During laryngoscopy, in both awake and unconscious subjects, most cervical motion occurs at the craniocervical junction; the subaxial cervical segments including and subjacent to C4 are minimally displaced [68,69]. During laryngoscopy and intubation in a cadaver model with an unstable C1 to C2 segment, the space available for the cord was narrowed to a greater degree by preintubation maneuvers than it was by intubation techniques; both nasal and oral intubation techniques resulted in similar amounts of space available for the cord narrowing, and cricoid pressure produced no significant movement at the craniocervical junction [70]. Four authors have evaluated the impact of commonly used immobilization techniques, including manual in-line immobilization (MILI), in limiting spinal motion in unstable spine models [71–74]. All concluded that the amount of movement measured during airway interventions was small, although it was not uniformly reduced compared with movement registered when no immobilization was applied. Three authors have also assessed the influence of the type of laryngoscope blade on the spinal movements generated during direct laryngoscopy and overall, there seems to be little difference in the magnitudes of spinal movement relative to the type of blade used during direct laryngoscopy [73,75,76].

Cervical spine movements are generally less when rigid indirect laryngoscopes are used compared with the direct laryngoscope, with the notable exception of the Glidescope, which results in similar magnitudes of movement [76–81]. Visualization of the glottis is also improved with the use of the rigid laryngoscopes. The insertion of laryngeal mask airways results in little spinal movement, although insertion may exert high pressures against the upper cervical vertebrae [82,83]. The clinical relevance of these findings has yet

to be clarified. Finally, spinal movements resulting from cricothyrotomy are small and similar to those recorded during other airway interventions [84].

Patients presenting for spinal surgery often arrive in the operating room wearing cervical collars. These collars reduce cervical movement somewhat and may afford a degree of comfort to patients with cervical pain aggravated by movement. Goutcher and Lochhead [85] concluded that the presence of a semirigid collar reduced mouth opening and interfered with airway management; removal of the anterior portion of the collar before attempts at tracheal intubation was encouraged. If it is believed that spinal immobilization is desirable during airway interventions, removal of the anterior portion should be undertaken only when it is feasible to replace it with another form of spinal immobilization, such as MILI.

The goal of MILI is to apply sufficient forces to the head and neck so as to limit the movement that might result during airway management. The intention is to apply forces that are equal in magnitude and opposite in direction to those being generated by the laryngoscopist to keep the head and neck in the neutral position. Avoiding traction forces during the application of MILI may be particularly important when there is gross spinal instability [71,86,87]. MILI reduces total spinal movement during the process of laryngoscopy and tracheal intubation [83], although Lennarson and colleagues [71,72] were unable to demonstrate that it resulted in reductions in movement at the site of instability in cadaver models.

Although MILI seems to have the least impact of all immobilization techniques on airway management, it may make direct laryngoscopy more difficult in some patients than if no immobilizing forces are being applied [73,88–90]. Anterior laryngeal or cricoid pressure often improves the view of the larynx when the neck is immobilized with MILI. Concern has been expressed in the past regarding the use of anterior cervical pressure in patients at risk for cervical instability, but Donaldson and colleagues [70] reported that application of cricoid pressure did not result in movement in a cadaver model of an injured upper cervical spine.

If the cervical spine is grossly unstable, consideration should be given to both intubating the trachea and positioning the patient while they are still awake. This can be accomplished with judicious sedation and generous application of local anesthesia to both the trachea and the skull before intubation and caliper placement. Although a prudent approach, it should be recognized that only a gross neurologic assessment is possible following positioning, and its accuracy may be diminished by the administered sedation.

The clinical practice of airway management in patients with cervical spine injury

A number of authors have reported their experiences and outcomes relating to airway management of cervical spine–injured patients; the most common management technique described has been the use of the

direct laryngoscope [91–100]. These studies are limited by both their small sample size and their retrospective nature. They reveal, however, that neurologic deterioration in spine-injured patients is uncommon after airway management, even in high-risk patients undergoing urgent tracheal intubation facilitated by direct laryngoscopy. They are not sufficient to rule out the potential that airway management provided in isolation or as part of a more complex clinical intervention, even provided with the utmost care, may rarely result in neurologic injury.

McLeod and Calder [101] examined the association between the use of the direct laryngoscope in patients and subsequent spinal injury or pathology. Six reports dealing with 10 patients in whom it was alleged that direct laryngoscopy contributed to a neurologic injury were reviewed [102–107]. With the possible exception of one case, they concluded after review and analysis of the case reports that the reports failed to provide sufficient data to allow them to make the determination that the use of the direct laryngoscope was the cause of the neurologic injuries reported.

There is considerable enthusiasm, particularly among anesthesiologists, for the use of the fiberoptic bronchoscope in patients with cervical spine disease, injury, or instability. There is a report detailing the successful use of the bronchoscope to facilitate awake intubation in 327 consecutive patients presenting for elective cervical spine surgery; the bulk of the procedures were surgeries for cervical disk prolapse and there were no patients with traumatic injuries included in the review [108]. Although the procedure was well tolerated by most of the patients, 38 (12%) developed low oxygen saturations; in this group, the mean oxygen saturation measured by pulse oximetry was 84 ± 4 (range, 72%–89%).

Airway complications after cervical spine surgery

Airway complications are common after anterior cervical spine surgery and may range from acute airway obstruction to chronic vocal cord dysfunction [109]. Variables associated with postoperative airway complications are an exposure involving more than three vertebral bodies or involving C2, C3, or C4; a blood loss of greater than 300 mL; an operative time greater than 5 hours; and combined anteroposterior cervical spine surgery [109,110]. Vocal cord paralysis resulting from recurrent laryngeal nerve palsy is the most common otolaryngologic complication after anterior cervical spine surgery; the incidence is variable in the reports available [111,112]. The incidence of clinically symptomatic (hoarseness) postoperative recurrent laryngeal nerve palsy may be as high as 8% with prospective assessment, and that of asymptomatic palsy twice that rate. The nerve dysfunction is transient and most cases are resolved at 3 months. Airway complications may also occur after cervical spine surgery performed in the prone position and consist primarily of laryngeal edema and macroglossia [113]. Decreased venous return from the face and upper airway has been

implicated as an etiologic factor; prolonged operations and extreme flexion positioning may increase the risk.

Postoperative visual loss after spinal surgery

Postoperative vision loss is a rare complication of spine surgery and more commonly associated with lumbar and thoracic procedures [114,115]. Only 4 (5%) of the 93 cases reported to the American Society of Anesthesiologists Postoperative Visual Loss Registry involved surgery at either the cervical or cervicothoracic levels [115]. The patients were generally healthy with a mean age of 50 years and most of the postoperative vision loss cases resulted from ischemic optic neuropathy. Surgery tended to be extensive, involving multiple levels in most patients; mean anesthetic durations were in excess of 9 hours and blood losses averaged 2 L.

Summary

Most patients presenting for cervical spine surgery do so because of age-related degenerative processes, which cause pain and usually minor degrees of neurologic compromise. The surgical procedures are usually limited in magnitude and the degree of difficulty anticipated with airway management is typically proportional to the biomechanical impact of the underlying disease process. A much smaller number present with severely degraded anatomy and the surgical procedures are far more invasive and high-risk and often intended to provide for a degree of pain palliation and to maintain ambulatory function. Some in this population have limited life prospects (eg, metastatic cancer), but many obtain substantial benefit from the surgery with improved quality of life. Careful preoperative evaluation, appropriate diagnostic imaging, and an approach to care formulated by collegial interaction between anesthesiologist and surgeon serves these patients well.

References

[1] Prescher A. Anatomy and pathology of the aging spine. Eur J Radiol 1998;27(3):181–95.
[2] Jofe MH, White AA, Panjabi MM. Clinically relevant kinematics of the cervical spine. In: The Cervical Spine Research Society. The cervical spine. 2nd edition. Philadelphia: JB Lippincott; 1989. p. 57–69.
[3] Koolstra JH, van Eijden TMGJ. Functional significance of the coupling between head and jaw movements. J Biomech 2004;37(9):1387–92.
[4] Mashour GA, Sandberg WS. Craniocervical extension improves the specificity and predictive value of the Mallampati airway evaluation. Anesth Analg 2006;103(5):1256–9.
[5] Calder I, Calder J, Crockard HA. Difficult direct laryngoscopy in patients with cervical spine disease. Anaesthesia 1995;50(9):756–63.
[6] Bouchard-Chabot A, Lioté F. Cervical spine involvement in rheumatoid arthritis: a review. Joint Bone Spine 2002;69(2):141–54.

[7] Boden S, Dodge L, Bohlman H, et al. Rheumatoid arthritis of the cervical spine. J Bone Joint Surg Am 1993;75(9):1282–97.
[8] Cusick JF, Yoganandan N. Biomechanics of the cervical spine 4: major injuries. Clin Biomech 2002;17(1):1–20.
[9] Banerjee R, Palumbo MA, Fadale PD. Catastrophic cervical spine injuries in the collision sport athlete, Part 1. Epidemiology, functional anatomy, and diagnosis. Am J Sports Med 2004;32(4):1077–87.
[10] Pavlov H, Torg JS, Robie B, et al. Cervical spinal stenosis: determination with vertebral body ratio method. Radiology 1987;164(3):771–5.
[11] Torg JS, Corcoran TA, Thibault LE, et al. Cervical cord neurapraxia: classifications, pathomechanics, morbidity, and management guidelines. J Neurosurg 1997;87(6): 843–50.
[12] Keene JS, Fischer SP, Vanderby R, et al. Significance of acute posttraumatic bony encroachment of the neural canal. Spine 1989;14(8):799–802.
[13] Panjabi MM, Yue JJ, Dvorak J, et al. Cervical spine kinematics and clinical instability. In: Clark CR, editor. The cervical spine. 4th edition. Philadelphia: Lippincott, Williams & Wilkins; 2005. p. 55–78.
[14] Paxinos O, Ghanayem AJ. Biomechanics of nonacute cervical spine trauma. In: Clark CR, editor. The cervical spine. 4th edition. Philadelphia: Lippincott, Williams & Wilkins; 2005. p. 102–9.
[15] Henderson FC, Geddes JF, Vaccaro AR, et al. Stretch-associated injury in cervical spondylotic myelopathy: new concept and review. Neurosurgery 2005;56(5):1101–13.
[16] Ching RP, Watson NA, Carter JW, et al. The effect of post-injury spinal position on canal occlusion in a cervical spine burst fracture model. Spine 1997;22(15):1710–5.
[17] Graham CB III, Wippold FJ, Bae KT, et al. Comparison of CT myelography performed in the prone positions in the detection of cervical spinal stenosis. Clin Radiol 2001;56(1): 35–9.
[18] Carlson GD, Gorden CD, Oliff HS, et al. Sustained spinal cord compression. Part I: time-dependent effect long-term pathophysiology. J Bone Joint Surg Am 2003;85(1):86–94.
[19] Benner BG. Etiology, pathogenesis, and natural history of discogenic neck pain, radiculopathy, and myelopathy. In: The Cervical Spine Research Society Editorial Committee. The cervical spine. 3rd edition. Philadelphia: Lippincott – Raven; 1998. p. 735–40.
[20] Lee TC, Yang LC, Chen HJ. Effect of patient position and hypotensive anesthesia on inferior vena caval pressure. Spine 1998;23(8):941–7.
[21] Bindal AK, Dunker SB, Tew JM Jr. Chiari 1 malformation: classification and management. Neurosurgery 1995;37(6):1069–74.
[22] Milhorat TH, Chou MW, Trinidad EM, et al. Chiari I malformations redefined: clinical and radiographic findings for 364 symptomatic patients. Neurosurgery 1999;44(5): 1005–17.
[23] Karasick D, Schweitzer ME, Vaccaro AR. The traumatized cervical spine in Klippel-Feil syndrome: imaging features. Am J Roentgenol 1998;170(1):85–8.
[24] Ulmer JL, Elster AD, Ginsberg LE, et al. Klippel-Feil syndrome: CT and MR of acquired and congenital abnormalities of cervical spine and cord. J Comput Assist Tomogr 1993; 17(2):215–24.
[25] Tracy MR, Dormans JP, Kusumi K. Klippel-Feil syndrome: clinical features and current understanding of etiology. Clin Orthop 2004;424:183–90.
[26] Crosby ET, Grahovac S. Diffuse idiopathic skeletal hyperostosis: an unusual cause of difficult intubation. Can J Anaesth 1993;40(1):54–8.
[27] Mader R. Clinical manifestations of diffuse idiopathic skeletal hyperostosis of the cervical spine. Semin Arthritis Rheum 2002;32(2):130–5.
[28] Naik B, Lobato EB, Sulek CA. Dysphagia, obstructive sleep apnea, and difficult fiberoptic intubation secondary to diffuse idiopathic skeletal hyperostosis. Anesthesiology 2004; 100(5):1311–2.

[29] Sreedharan S, Li YH. Diffuse idiopathic skeletal hyperostosis with cervical spinal cord injury: a report of 3 cases and a literature review. Ann Acad Med Singap 2005;34(3): 257–61.
[30] Takenaka I, Urakami Y, Aoyama K, et al. Severe subluxation in the sniffing position in a rheumatoid patient with anterior atlantoaxial subluxation. Anesthesiology 2004;101(5): 1235–7.
[31] Shen FH, Samartzis D, Jenis LG, et al. Rheumatoid arthritis: evaluation and surgical management of the cervical spine. Spine J 2004;4(6):689–700.
[32] Borenstein D. Inflammatory arthritides of the spine: surgical versus nonsurgical treatment. Clin Orthop 2006;443:208–21.
[33] Shen FH, Samartzis D. Surgical management of lower cervical spine fracture in ankylosing spondylitis. J Trauma 2006;61(4):1005–9.
[34] Belanger TA, Milam RA IV, Roh JS, et al. Cervicothoracic extension osteotomy for chin-on-chest deformity in ankylosing spondylitis. J Bone Joint Surg Am 2005;87(8):1732–8.
[35] Grisolia A, Bell RL, Peltier LF. Fractures and dislocations of the spine complicating ankylosing spondylitis: a report of six cases. Clin Orthop 2004;422:129–34.
[36] Carette S, Fehlings MG. Cervical radiculopathy. N Engl J Med 2005;353(4):392–9.
[37] Orr RD, Zdeblick TA. Cervical spondylotic myelopathy: approaches to surgical treatment. Clin Orthop 1999;359:58–66.
[38] Emery SE. Cervical spondylotic myelopathy: diagnosis and treatment. J Am Acad Orthop Surg 2001;9(6):376–88.
[39] Muhle C, Weinert D, Falliner A, et al. Dynamic changes of the spinal canal in patients with cervical spondylosis at flexion and extension using magnetic imaging. Invest Radiol 1998; 33(8):444–9.
[40] Simmons ED, Zheng Y. Vertebral tumours: surgical versus nonsurgical treatment. Clin Orthop 2006;443:233–47.
[41] Jenis LG, Dunn EJ, An HS. Metastatic disease of the cervical spine. Clin Orthop 1999;359: 89–103.
[42] Tasdemiroglu E, Kaya AH, Bek S, et al. Neurologic complications of cancer. Part 1: central nervous system metastasis. Neurosurgery Quarterly 2004;14(2):71–83.
[43] Vrionis FD, Small J. Surgical management of metastatic spinal neoplasms. Neurosurg Focus 2003;15(5):1–8.
[44] Liu JK, Apfelbaum RI, Chiles BW III, et al. Cervical spine metastasis: anterior reconstruction and stabilization techniques after tumor resection. Neurosurg Focus 2003;15(5):1–7.
[45] Crosby ET. Airway management in adults after cervical spine trauma. Anesthesiology 2006;104(6):1293–318.
[46] Goldberg W, Mueller C, Panacek E, et al. Distribution and patterns of blunt traumatic cervical spine injury. Ann Emerg Med 2001;38(1):17–21.
[47] Holly LT, Kelly DF, Counelis GJ, et al. Cervical spine trauma associated with moderate and severe head injury: incidence, risk factors, and injury characteristics. J Neurosurg 2002;96(Suppl 3):285–91.
[48] Demetriades D, Charalambides K, Chahwan S, et al. Nonskeletal cervical spine injuries: epidemiology and diagnostic pitfalls. J Trauma 2000;48(4):724–7.
[49] Hackl W, Hausberger K, Sailer R, et al. Prevalence of cervical spine injuries in patients with facial trauma. Oral Surg Oral Med Oral Pathol Oral Radiol Endod 2001;92(4):370–6.
[50] Blackmore CC, Emerson SS, Mann FA, et al. Cervical spine imaging in patients with trauma: determination of fracture risk to optimize use. Radiology 1999;211(3):759–65.
[51] Sekhon LHS, Fehlings MG. Epidemiology, demographics and pathophysiology of acute spinal cord injury. Spine 2001;26(Suppl):S2–12.
[52] Reid DC, Henderson R, Saboe L, et al. Etiology and clinical course of missed spine fractures. J Trauma 1987;27(9):980–6.
[53] Davis JW, Phreaner DL, Hoyt DB, et al. The etiology of missed cervical spine injuries. J Trauma 1993;34(3):342–6.

[54] Poonnoose PM, Ravichandran G, McClelland M. Missed and mismanaged injuries of the spinal cord. J Trauma 2002;53(2):314–20.
[55] Hadley MN. Guidelines of the American Association of neurologic surgeons and the congress of neurologic surgeons: radiographic assessment of the cervical spine in asymptomatic trauma patients. Neurosurgery 2002;50(Suppl):S30–5.
[56] Lindsey RW, Gugala Z. Clearing the cervical spine in trauma patients. In: Clark CR, editor. The cervical spine. 4th edition. Philadelphia: Lippincott, Williams & Wilkins; 2005. p. 375–86.
[57] Hadley MN. Guidelines of the American Association of Neurologic Surgeons and the Congress of Neurologic Surgeons. Radiographic spinal assessment in symptomatic trauma patients. Neurosurgery 2002;50(Suppl):S36–43.
[58] Morris CGT, McCoy E. Clearing the cervical spine in unconscious polytrauma victims, balancing risk and effective screening. Anaesthesia 2004;59(5):464–82.
[59] Yablon IG, Ordia J, Mortara R, et al. Acute ascending myelopathy of the spine. Spine 1989; 14(10):1084–9.
[60] Belanger E, Picard C, Lacerte D, et al. Subacute posttraumatic ascending myelopathy after spinal cord injury: report of three cases. J Neurosurg 2000;93(Suppl 2):294–9.
[61] Schmidt BJ. Subacute delayed ascending myelopathy after low spine injury: case report and evidence of a vascular mechanism. Spinal Cord 2006;44(5):322–5.
[62] Kaiser JA, Holland BA. Imaging of the cervical spine. Spine 1998;23(24):2701–12.
[63] Khanna AJ, Carbone JJ, Kebaish KM, et al. Magnetic resonance imaging of the cervical spine. J Bone Joint Surg Am 2002;84(Suppl 2):70–80.
[64] Foster MR. A functional classification of spinal instrumentation. Spine J 2005;5(6):682–94.
[65] Tokunaga D, Hase H, Mikami Y, et al. Atlanotaxial subluxation in different intraoperative head positions in patients with rheumatoid arthritis. Anesthesiology 2006;104(4):675–9.
[66] Aprahamian C, Thompson BM, Finger WA, et al. Experimental cervical spine injury model: evaluation of airway management and splinting techniques. Ann Emerg Med 1984;13(8):584–7.
[67] Hauswald M, Sklar DP, Tandberg D, et al. Cervical spine movement during airway management: cinefluoroscopic appraisal in human cadavers. Am J Emerg Med 1991;9(6): 535–8.
[68] Sawin PD, Todd MM, Traynelis VC, et al. Cervical spine motion with direct laryngoscopy and orotracheal intubation: an in vivo cinefluoroscopic study of subjects without cervical abnormality. Anesthesiology 1996;85(1):26–36.
[69] Horton WA, Fahy L, Charters P. Disposition of the cervical vertebrae, atlanto-axial joint, hyoid and mandible during x-ray laryngoscopy. Br J Anaesth 1989;63(4):435–8.
[70] Donaldson WF III, Heil BV, Donaldson VP, et al. The effect of airway maneuvers on the unstable C1-C2 segment: a cadaver study. Spine 1997;22(11):1215–8.
[71] Lennarson PJ, Smith DW, Sawin PD, et al. Cervical spinal motion during intubation: efficacy of stabilization maneuvers in the setting of complete segmental instability. J Neurosurg (Spine 2) 2001;94:265–70.
[72] Lennarson PJ, Smith D, Todd MM, et al. Segmental cervical spine motion during orotracheal intubation of the intact and injured spine with and without external stabilization. J Neurosurg (Spine 2) 2000;92:201–6.
[73] Gerling MC, Davis DP, Hamilton RS, et al. Effects of cervical spine immobilization technique and laryngoscope blade selection on an unstable cervical spine in a cadaver model of intubation. Ann Emerg Med 2000;36(4):293–300.
[74] Brimacombe J, Keller C, Kunzel KH, et al. Cervical spine motion during airway management: a cinefluoroscopic study of the posteriorly destabilized third cervical vertebrae in human cadavers. Anesth Analg 2000;91(5):1274–8.
[75] MacIntyre PR, McLeod ADM, Hurley R, et al. Cervical spine movements during laryngoscopy: comparison of the Macintosh and McCoy laryngoscope blades. Anaesthesia 1999; 54(10):413–8.

[76] Hastings RH, Vigil AC, Hanna R, et al. Cervical spine movement during laryngoscopy with the Bullard, Macintosh and Miller laryngoscopes. Anesthesiology 1995;82(4):859–69.
[77] Watts ADJ, Gelb AW, Bach DB, et al. Comparison of Bullard and Macintosh laryngoscopes for endotracheal intubation of patients with a potential cervical spine injury. Anesthesiology 1997;87(6):1335–42.
[78] Cooper SD, Benumof JL, Ozaki GT. Evaluation of the Bullard laryngoscope using the new intubating stylet: comparison with conventional laryngoscopy. Anesth Analg 1994;79(5): 965–70.
[79] Rudolph C, Schneider JP, Wallenborn J, et al. Movement of the upper cervical spine during laryngoscopy: a comparison of the Bonfils intubation fiberscope and the Macintosh laryngoscope. Anaesthesia 2005;60(7):668–72.
[80] Agro F, Barzoi G, Montechia F. Tracheal intubation using a Macintosh laryngoscope or a Glidescope in 15 patients with cervical spine immobilization. Br J Anaesth 2003;90(5): 705–6.
[81] Turkstra TP, Craen RA, Pelz DM, et al. Cervical spine motion: a fluoroscopic comparison during intubation with lighted stylet, Glidescope, and Macintosh laryngoscope. Anesth Analg 2005;101(3):910–5.
[82] Kihara S, Watanabe S, Brimacombe J, et al. Segmental cervical spine movement with the intubating laryngeal mask during manual in-line stabilization in patients with cervical pathology undergoing cervical spine surgery. Anesth Analg 2000;91(1):195–200.
[83] Keller C, Brimacombe J, Keller K. Pressures exerted against the cervical vertebrae by the standard and intubating laryngeal mask airways: a randomized, controlled, cross-over study in fresh cadavers. Anesth Analg 1999;89(5):1296–300.
[84] Gerling MC, Davis DP, Hamilton RS, et al. Effect of surgical cricothyrotomy on the unstable cervical spine in a cadaver model of intubation. J Emerg Med 2001;20(1):1–5.
[85] Goutcher CM, Lochhead V. Reduction in mouth opening with semi-rigid cervical collars. Br J Anaesth 2005;95(3):344–8.
[86] Bivins HG, Ford S, Bezmalinovic Z, et al. The effect of axial traction during orotracheal intubation of the trauma victim with an unstable cervical spine. Ann Emerg Med 1988; 17(1):25–9.
[87] Majernick TG, Bienek R, Houston JB, et al. Cervical spine movement during orotracheal intubation. Ann Emerg Med 1986;15(4):417–20.
[88] Heath KJ. The effect on laryngoscopy of different cervical spine immobilization techniques. Anaesthesia 1994;49(10):843–5.
[89] Nolan JP, Wilson ME. Orotracheal intubation in patients with potential cervical spine injuries. Anaesthesia 1993;48(7):630–3.
[90] Wood PR, Dresner M, Hayden Smith J, et al. Direct laryngoscopy and cervical spine stabilization. Anaesthesia 1994;49(1):77–8.
[91] Meschino A, Devitt JH, Koch JP, et al. The safety of awake tracheal intubation in cervical spine injury. Can J Anaesth 1992;39(2):114–7.
[92] Holley J, Jordan R. Airway management in patients with unstable cervical spine fractures. Ann Emerg Med 1989;18(11):1237–9.
[93] Rhee KJ, Green W, Holcroff JW, et al. Oral intubation in the multiply injured patient: the risk of exacerbating spinal cord damage. Ann Emerg Med 1990;19(5):511–4.
[94] Scanell G, Waxman K, Tommaga G, et al. Orotracheal intubations in trauma patients with cervical fractures. Arch Surg 1993;128(8):903–6.
[95] Shatney CH, Brunner RD, Nguyen TQ. The safety of orotracheal intubation in patients with unstable cervical spine fracture or high spinal cord injury. Am J Surg 1995;170(6): 676–80.
[96] Talucci RC, Shaikh KA, Schwab CW. Rapid sequence induction with oral endotracheal intubation in the multiply injured patient. Am Surg 1988;54(4):185–7.
[97] Suderman VS, Crosby ET, Lui A. Elective oral tracheal intubation in cervical spine-injured adults. Can J Anaesth 1991;38(6):785–9.

[98] McCrory C, Blunnie WP, Moriarty DC. Elective tracheal intubation in cervical spine injuries. Ir Med J 1999;90(6):234–5.
[99] Wright SW, Robinson GG II, Wright MB. Cervical spine injuries in blunt trauma patients requiring emergent endotracheal intubation. Am J Emerg Med 1992;10(2):104–9.
[100] Norwood S, Myers MB, Butler TJ. The safety of emergency neuromuscular blockade and orotracheal intubation in the acutely injured trauma patient. J Am Coll Surg 1994;179(6): 646–52.
[101] McLeod ADM, Calder I. Spinal cord injury and direct laryngoscopy: the legend lives on. Br J Anaesth 2000;84(6):705–8.
[102] Farmer J, Vaccaro A, Albert TJ, et al. Neurologic deterioration after cervical spinal cord injury. J Spinal Disord 1998;11(3):192–6.
[103] Muckart DJ, Bhagwanjee S, van der Merwe R. Spinal cord injury as a result of endotracheal intubation in patients with undiagnosed cervical spine fractures. Anesthesiology 1997; 87(2):418–20.
[104] Redl G. Massive pyramidal tract signs after endotracheal intubation: a case report of spondyloepiphyseal dysplasia congenital. Anesthesiology 1998;89(5):1262–4.
[105] Yan K, Diggan MF. A case of central cord syndrome caused by intubation: a case report. J Spinal Cord Med 1997;20(2):230–2.
[106] Yaszemski MJ, Shepler TR. Sudden death from cord compression associated with atlantoaxial instability in rheumatoid arthritis. Spine 1990;15(4):338–41.
[107] Hastings RH, Kelley SD. Neurologic deterioration associated with airway management in a cervical spine-injured patient. Anesthesiology 1993;78(3):580–3.
[108] Fuchs G, Schwarz G, Baumgartner A, et al. Fiberoptic intubation in 327 patients with lesions of the cervical spine. J Neurosurg Anesthesiol 1999;11(1):11–6.
[109] Sagi HC, Beutler W, Carroll E, et al. Airway complications associated with surgery on the anterior cervical spine. Spine 2002;27(9):949–53.
[110] Terao Y, Matsumoto S, Yamashita K, et al. Increased incidence of emergency airway management after combined anterior-posterior cervical spine surgery. J Neurosurg Anesthesiol 2004;16(4):282–6.
[111] Jung A, Schramm J, Lehnerdt K, et al. Recurrent laryngeal nerve palsy during anterior cervical spine surgery: a prospective study. J Neurosurg Spine 2005;2(2):123–7.
[112] Apfelbaum RI, Kriskovich MD, Haller JR. On the incidence, cause, and prevention of recurrent laryngeal nerve palsies during anterior cervical spine surgery. Spine 2000; 25(22):2906–12.
[113] Sinha A, Agarwal A, Gaur A, et al. Oropharyngeal swelling and macroglossia after cervical spine surgery in the prone position. J Neurosurg Anesthesiol 2001;13(3):237–9.
[114] Stevens WR, Glazer PA, Kelley SD, et al. Ophthalmic complications after spine surgery. Spine 1997;22(12):1319–24.
[115] Lee LA, Roth S, Posner KL, et al. The American Society of anesthesiologists postoperative visual loss registry: analysis of 93 spine surgery cases with postoperative visual losses. Anesthesiology 2006;105(4):652–9.