

The Complexities of Tracheal Intubation With Direct Laryngoscopy and Alternative Intubation Devices

Richard M. Levitan, MD, James W. Heitz, MD, Michael Sweeney, CRNP, Richard M. Cooper, MD

From the Jefferson Medical College and Thomas Jefferson University Hospital, Philadelphia, PA (Levitan, Heitz); Pottstown Memorial Medical Center, Pottstown, PA (Sweeney); and the University of Toronto, Toronto General Hospital, Toronto, Ontario, Canada (Cooper).

Intubation research on both direct laryngoscopy and alternative intubation devices has focused on laryngeal exposure and not the mechanics of actual endotracheal tube delivery or insertion. Although there are subtleties to tracheal intubation with direct laryngoscopy, the path of tube insertion and the direct line of sight are relatively congruent. With alternative intubation devices, this is not the case. Video or optical elements in alternative intubation devices permit looking around the curve of the tongue, without a direct line of sight to the glottic opening. With these devices, laryngeal exposure is generally the simple part of the procedure, and conversely, tube delivery to the glottic opening and advancement into the trachea are sometimes not straightforward. This article presents the mechanical and optical complexities of endotracheal tube insertion in both direct laryngoscopy and alternative devices. An understanding of these complexities is critical to facilitate rapid tracheal intubation and to minimize unsuccessful attempts. [Ann Emerg Med. 2011;57:240-247.]

A **podcast** for this article is available at www.annemergmed.com.

0196-0644/\$-see front matter

Copyright © 2010 by the American College of Emergency Physicians.

doi:10.1016/j.annemergmed.2010.05.035

BREAKING DOWN THE COMPLEXITIES OF ENDOTRACHEAL TUBE INSERTION

Direct laryngoscopy has been the standard technique for tracheal intubation for almost a century. However, the last 2 decades have seen the development of myriad alternative intubation devices. Alternative intubation devices with video or optical imaging have many advantages over direct laryngoscopy: easier laryngeal exposure with less force, ability to achieve a laryngeal view despite unfavorable anatomy for direct laryngoscopy, and an opportunity for multiple clinicians to observe and watch the procedure. Nuances in design of these alternative devices directly affect their clinical use. Many of the newer devices use indirect methods for laryngeal sighting, and the devices require a different appreciation of the components of tracheal intubation.

Tracheal intubation involves 3 distinct challenges: laryngeal sighting, delivering the tube to the glottic opening, and advancing the tube beyond the target and into the trachea. With direct laryngoscopy, sighting the larynx occurs through a direct line of sight by mechanically controlling the tongue and the epiglottis. A curved blade indirectly lifts the epiglottis (by pressure on the hyoepiglottic ligament at the vallecula), whereas a straight blade lifts the epiglottis directly. Video and mirror laryngoscopes achieve laryngeal exposure through indirect imaging, ie, using video cameras, or a series of mirrors and prisms. These devices look around the curve of the tongue and bypass the mechanical challenges of creating a direct line of sight to the larynx. Video laryngoscopes include the GlideScope

(Verathon Medical, Bothell, WA), McGrath Video Laryngoscope (Aircraft Medical, Edinburgh, Scotland), Pentax Airway Scope (Ambu, Copenhagen, Denmark), and Storz C-Mac (Karl Storz, Tuttlingen, Germany). The AirTraQ Optical Laryngoscope (Prodol Meditec, Guecho Vizcaya, Spain) has no video camera but instead a combination of mirrors, prisms, and a hooded eyepiece. A video camera can be connected to the eyepiece, however, allowing display on an external monitor.

ACHIEVING LARYNGEAL VIEW AND DEFINING THE VIEW AXIS

How an intubation device achieves laryngeal visualization (and deals with the tongue) affects how a tube is delivered to the glottic opening and also the angle at which a tube passes into the trachea. A standardized way to compare this across different devices is to look at each device on an angle grid (Figure 1). The view axis is the line of view, created either by a direct line of sight or through an imaging mechanism.

At the top of this set of pictures are standard straight and curved blade laryngoscopes. A Miller blade (top left) has a very defined and limited view axis to the target, created by the blade's narrow spatula and short flange height. This view axis is a straight line perpendicular to the handle, aligning along the horizontal line (90 to 270 degrees on a superimposed protractor). A Macintosh blade (top right) permits the view axis to pivot, depending on how the blade is positioned and where the operator is looking. The amount of pivoting is restricted by




Figure 1. A standardized approach to assessing the view axis of different intubation devices. In the first row are standard Miller and Macintosh blades. The view axis in direct laryngoscopy is straight: a direct line of sight, 90 degrees to the handles, along the 90- to 270-degree line, marked with a symbolic eye at 90 degrees. It is possible to slightly pivot the view axis around a curved Macintosh blade (shown on right, with superimposed images of the pivoting blade), but the line of sight still remains straight. In the second row, from left to right, are the McGrath, GlideScope, and C-Mac. The bright light in each image is from the video laryngoscope itself and roughly corresponds to the camera perspective from each device. These devices have a view axis of approximately 270 to 300 degrees (measured from the vertical axis); the blade tips point roughly to 290 degrees. In the bottom row, from left to right, are the AirTraQ and the Pentax AirWay Scope. These devices have a view axis of approximately 260 to 270 degrees, noticeably less steep than the nonchanneled video laryngoscopes in the row above.

the flange height of the blade, the curve of the spatula, and patient-specific features (mouth opening, upper dentition, tongue characteristics, epiglottis lift, etc). Given that laryngeal sighting is by direct line of sight, however, the view axis is always straight, even though it may not be perpendicular to the handle.

Assuming that the vertical axis of the laryngoscope handle is given a zero-degree reference value, the operator's line of sight to the target during direct laryngoscopy always approximates 90 degrees (albeit with minor pivoting about the spatula with a curved blade). With video and optical devices (discussed below), the view angle is determined by the imaging device orientation (not connected in any direct way with the device handle axis), but for purposes of comparison across devices, the vertical axis of the handle is given a reference value of zero.

In the next row of devices of Figure 1 are the McGrath, GlideScope, and Storz C-Mac (from left to right). Notice that the distal tips of these video laryngoscope blades point toward

the 290-degree mark on the superimposed protractor.

Compared with direct laryngoscopy, these devices provide a look around the curve from 0 degrees (the handle axis reference point), counterclockwise, to a visual axis of approximately 270 to 300 degrees. The view axis of these devices roughly correlates with the projected light coming from the blade of each device (Figure 1). The cameras used by these devices have a wide field of view both up and down and left to right that includes the distal tip of their blades (Figure 2). The result is a supraepiglottic panoramic perspective on the larynx, from above the epiglottis and posterior to the base of the tongue. Devices have different camera specifications and varying optical distortion (Figure 2).

The third row in Figure 1 shows the AirTraQ Optical Laryngoscope and the Pentax Airway Scope (Pentax AWS). These 2 devices have an integrated channel for endotracheal tube delivery. There are advantages and disadvantages to



Figure 2. The video and optical laryngoscopes all offer a wide field of view at the distal tip (approximately 4 to 6 cm), as shown by pointing the devices at a measuring grid of 1-cm dark squares. From left to right, the McGrath, GlideScope, C-Mac, AirTraq (with a video camera attached to the eyepiece), and the AirWay Scope. The lenses are not identical; each has its own field of view, and some have greater fisheye distortion. The McGrath (far left) has a slightly smaller field of view than the square, wider view of the GlideScope (second from the left) or the rectangular view of the C-Mac (middle). The AirTraq (second from the right) has a relatively smaller square field of view compared with the Pentax AWS (far right), which is much longer vertically than horizontally.

attaching a tube delivery channel to the imaging mechanism, which will be addressed below. The viewing angle (and distal blades) of these 2 devices is distinctly less steep than the devices without an integrated track. Even though the angle of their distal tips is close to the horizontal line, relative to the vertical axes they essentially offer a view to the larynx that is perpendicular to their vertical axis (approximately 260 to 270 degrees). Although the distal shape of the AirTraq, for example, is perpendicular from the main device axis, the view axis has been optically manipulated counterclockwise approximately 270 degrees, which is optically very different from direct laryngoscopy (even though the blades are also perpendicular to the main device axis) because the operator's eye position in direct laryngoscopy is approximately 90 degrees from the handle and the view is along the 90- to 270-degree line (marked by the eye symbol in Figure 1).

DELIVERING THE TUBE TO THE TARGET: GETTING AROUND THE CURVATURE OF THE TONGUE TO THE GLOTTIC OPENING

After the larynx has been visualized, the second part of the intubation procedure involves delivering the tube to the glottic opening. The tall flange of a Macintosh blade permits sweeping the tongue leftward, providing a wide area for visualization and tube passage. Moving the tube tip to the glottic opening with both curved and straight blades has the potential to block target visualization, which depends on maintaining a direct line of sight. It is best to insert the tube from the extreme right corner of the mouth and then advance the tip to the glottis, coming from below the line of sight. This permits seeing the tip of the tube pass over the posterior laryngeal landmarks and into the trachea without blocking the target. A straight-to-cuff stylet shape with a 35-degree bend provides a narrow long-axis dimension for inserting the tube without blocking the line of sight¹ (Figure 3).

With the nonchanneled video laryngoscopes (GlideScope and McGrath), cameras positioned around the curve of the tongue visualize the target. The small flange on these devices is not used to sweep the tongue, and instead a midline approach is recommended.² Because the device is not creating a direct channel for tube passage, the tube must be maneuvered around the device and the tongue to the target. Although a stylet is not always needed, it can be very helpful for bringing the tube tip up to the target.^{2,3} Notice in Figure 1 how the curvature of the McGrath and GlideScope blades is noticeably forward of the vertical axis of these devices; this is different from the Storz C-Mac (second row, far right). In a study comparing performance of different videolaryngoscopes, a stylet was needed in 76% and 60% of cases with the McGrath and GlideScope, respectively.⁴ The manufacturer of the GlideScope now promotes a specialized stylet and endotracheal tube to aid insertion. The GlideRite stylet has a significant distal bend (approximately 70 degrees) relative to the proximal straight section (Figure 4). The McGrath has no specialized stylet, although any malleable stylet can be used to create a shape essentially matching the blade shape and then rotated into view. Although there is a tendency to focus on the video monitor, it is important to directly visualize the tube going into the mouth and around the tongue before it becomes visible on the video display. Perforations of the pharynx and hypopharynx have occurred with the GlideScope and the McGrath when operators have blindly inserted stylet-tipped tubes while focusing only on the video monitor.^{5,6}

The Storz C-Mac has a proximal flange shape similar to that of a curved laryngoscope blade. It is significantly larger than the flanges of the GlideScope and the McGrath, approximately 2.5 cm high at its base, versus the GlideScope, 1.5 cm, and the McGrath, 1.25 cm. The video camera on the C-Mac provides a look around the curve, but the proximal blade has a standard Macintosh form. Once the tube passes under the curve of the

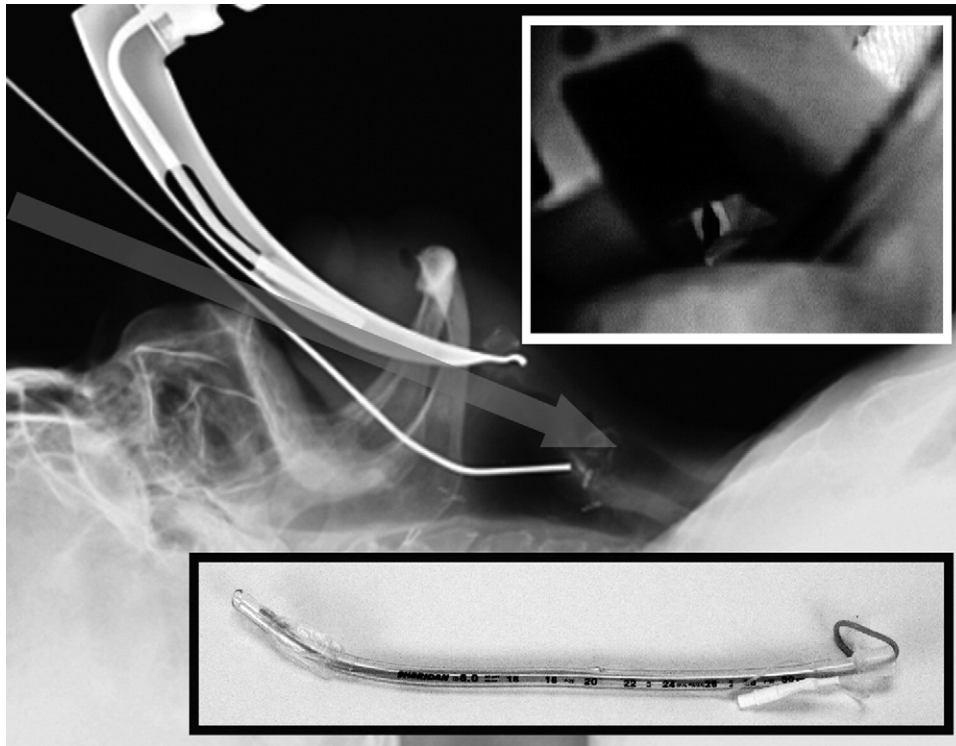


Figure 3. Cross-table lateral of curved blade laryngoscope and tube insertion in a cadaver, with metallic line representing a straight-to-cuff stylet. Inset at the top shows operator view insertion at the extreme corner of the mouth, with the tube coming up from below the line of sight (not blocking target). Inset bottom shows a straight-to-cuff stylet with an approximately 35 degree bend at the proximal cuff.

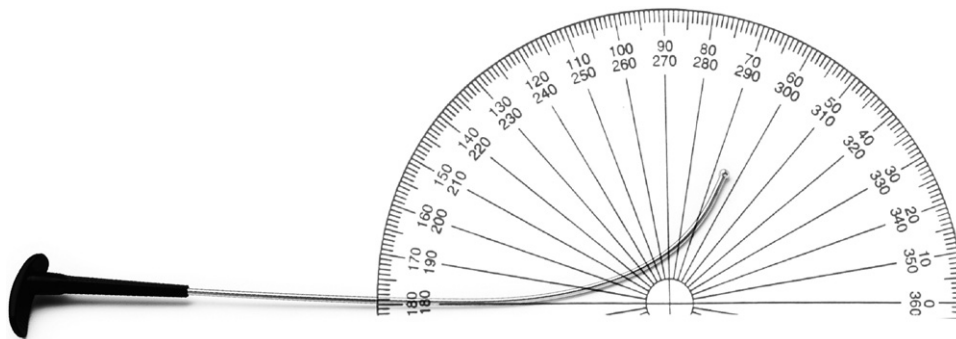


Figure 4. The GlideRite Stylet, promoted by the GlideScope manufacturer. The bend angle approximates 70 degrees. The large plastic proximal stop permits 1-handed retraction of the stylet after the tube tip has passed through the vocal cords.

blade, tube insertion can be completed by visualization on the video monitor. The shape and size of the proximal blade make tube delivery to the glottis with the C-Mac much more straightforward (similar to direct laryngoscopy) compared with that of the GlideScope or McGrath. The best way to understand this is to consider the trajectory a tube tip takes during direct laryngoscopy or with the C-Mac. Imagine if the tip of the tube could be followed with fluoroscopy from the mouth to the larynx. The tube tip is inserted into the oropharynx, travels relatively directly down to the hypopharynx, and is then tilted upward into the larynx. Conversely, with the McGrath or

GlideScope, the tube tip has to rotate sharply around the curvature of the blade (and around the tongue) and then up to the larynx.

Compared with the McGrath and GlideScope, in which stylets are needed for the majority of patients, a stylet is required in only about 10% of patients with the C-Mac.⁴ If a stylet is required with the C-Mac, a tube shape similar to that of direct laryngoscopy (straight-to-cuff, with a 35-degree “hockey-stick” bend) can be used for insertion under the blade and advancement into the trachea.

A potential disadvantage of the larger proximal flange of the C-Mac is that it can require greater mouth opening than the

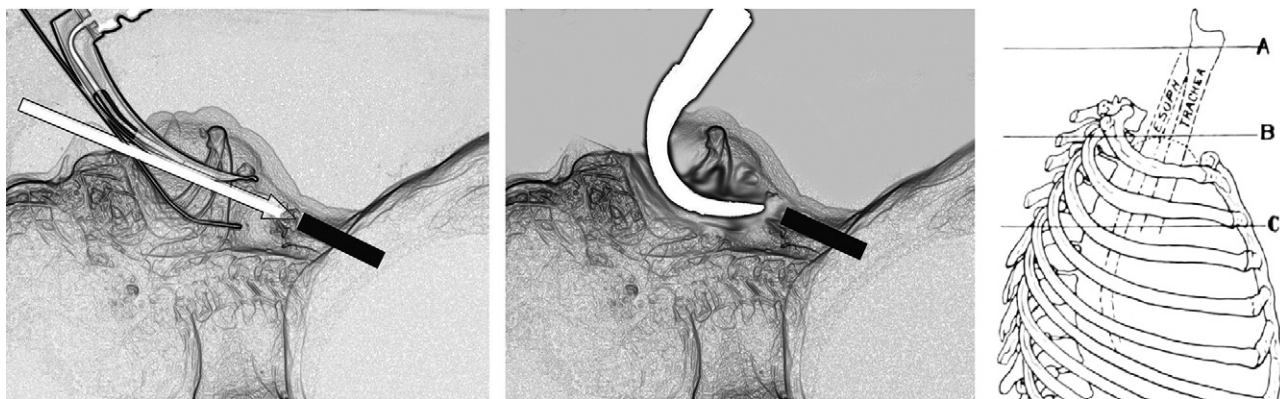

Figure 5. A stylized image of a standard laryngoscope and stylet in a cadaver (left), and the GlideScope (right) superimposed on the same image. The image was created from a lateral radiograph and then photo-manipulated to show only the edges. The tracheal axis is marked with a solid black line. On the left, the direct line of sight during laryngoscopy is shown as an open arrow. During direct laryngoscopy, the view axis and the axis of tube delivery (with a straight-to-cuff stylet) are relatively similar. The GlideScope curves sharply around the tongue and provides a videographic view of the larynx from the hypopharynx. The endotracheal tube must be directed around the curvature of the tongue and the device. At the far right is a drawing from Chevalier Jackson's 1922 text, *Bronchoscopy and Esophagoscopy: A Manual of Peroral Endoscopy*. Note that with the head held forward (similar in supine position to the head-elevated position recommended for direct laryngoscopy), the inclination of the upper trachea (at line A) is straight with the remainder of the trachea and tilts backward toward the spine. This tracheal angle orientation is tilted posteriorly to the spine compared with the upward-oriented curvature of the nonchanneled video laryngoscope blades.

smaller-flanged video laryngoscopes, depending on how much blade insertion is needed to obtain a video view of the larynx. Even though the view axis of the Storz C-Mac in Figure 1 appears similar to that of the GlideScope and McGrath, in vivo this may not be the case, given the mechanics of a significantly larger blade, especially in patients with a restricted mouth opening.

The AirTraq and Pentax AWS incorporate a tube channel to the right of the viewing axis, which solves the challenge of getting a tube around the tongue, and accordingly these devices do not require a stylet. Between the gap from the end of tube track to the glottic opening, however, tube delivery to the target may not be straightforward.⁷⁻⁹ The tube track and view axis are slightly incongruent, and a nonstyletted polyvinyl chloride tracheal tube has an inherent arcuate shape that curves the tube upward.¹⁰ Furthermore, the epiglottis is a potential obstacle, depending on the position of the blade tip and how effectively it elevates the epiglottis. Because the view axis and the tube track are connected, altering the direction of tube delivery requires manipulating the entire device. The tube cannot be independently directed toward the target. Some users have advocated the use of a tube introducer (aka, "bougie"), a stylet, or adjustment maneuvers to assist with tube insertion when using the Pentax AWS or AirTraq.⁷⁻⁹

The AirTraq can be used with the tip either in the vallecula or under the epiglottis edge; the Pentax AWS almost always requires that the epiglottis be lifted directly. Perhaps this results from the difference in view angle (and track angles); the Pentax product has a slightly lower-angled distal tip (approximately 260 degrees versus approximately 270). The devices also have subtle

differences in how an endotracheal tube exits, which in turn affects the movement of the tube tip, especially relative to the epiglottis and the posterior cartilages.^{8,9} The Pentax AWS has sighting markers on the miniature video screen that mark the tube tip direction when the tube is pushed through the channel.

ADVANCING A TUBE INTO THE TRACHEA: THE TRACHEAL AXIS AND THE ANTERIOR TRACHEAL RINGS

The final piece of the intubation challenge is advancing the endotracheal tube into the trachea. The trachea descends from the larynx into the thorax at a posterior angle compared with the angle of a curved blade at the base of the tongue (Figure 5, left panel). The disparity between these 2 angles is further exacerbated by atlanto-occipital extension. For both direct laryngoscopy and alternative devices, mouth opening and jaw distraction are optimized by keeping the face plane of the patient parallel to the ceiling and by avoiding overextension at the atlanto-occipital joint.

The disparity between the blade angle at the base of the tongue and the inclination of the trachea creates a potential problem for devices that use imaging to look around the curve, especially those with a small flange and steep view axis, such as the McGrath and GlideScope (Figure 5, center panel). A tube can be rotated around the curve of the tongue and even brought upward to the glottic opening, but the same curvature used to get around the tongue (and the curved blades of McGrath and GlideScope) will not pass into the trachea. The trachea descends posteriorly into the thorax (Figure 5, right panel), whereas the curvature of the video laryngoscopes points anteriorly from the

base of the tongue upward to the larynx (Figure 5, middle panel).

With sharply angled video laryngoscopes, the ability to image the larynx does not correlate with successful intubation. In a large series (728 patients) with the GlideScope, for instance, although 99% of patients had a grade 1 or 2 Cormack-Lehane laryngeal view, intubation efforts were abandoned in 3.7% of cases.² The authors noted: "Laryngeal exposure was rarely the cause of a failed intubation, but the inability to deliver the tracheal tube to a visualized larynx is both frustrating and largely avoidable" [by using the optimal technique].² In a study of the McGrath, laryngeal views were better with the McGrath compared with standard laryngoscopy, but time to intubation was much longer (47 versus 29 seconds), and 4 times as many patients had prolonged intubation (>70 seconds).¹¹ In a comparison of 3 video laryngoscopes, the smaller-flanged, sharply angled devices, the McGrath and the GlideScope, had longer mean intubation times than the C-Mac (41 [SD 25], 33 [SD 18], and 17 [SD 9] seconds, respectively).⁴

Apart from the difference between the inclination of the trachea and the curvature of the tongue, the anterior tracheal rings add a mechanical impediment to tube advancement (Figure 6, top). Even with direct laryngoscopy, too steep a bend angle on a stylet will cause the tube tip to catch on the tracheal rings. With direct laryngoscopy, a significant increase in mechanical insertion problems occurs when the bend angle of a straight-to-cuff stylet-tipped tube exceeds 35 degrees.¹ With bend angles greater than 35 degrees, the long-axis dimension of the tube (and bend) starts to exceed the diameter of the trachea, and the tip interacts with the tracheal rings at too steep an angle to advance.

Excessive stylet shaping (>35 degrees) can also create tube advancement problems with the Storz C-Mac. With the C-Mac and standard curved blade laryngoscopy, however, a sharp stylet bend is not needed to deliver the tube to the glottis because the proximal blade shape and orientation offers a relatively straighter route for tube insertion.

The McGrath and GlideScope require much greater tube bend angles than 35 degrees to navigate a tube around the curve of the tongue and to the target. The GlideRite stylet uses an angle of approximately 70 degrees (Figure 4). This bend angle does not allow the tube and stylet to be rotated into the trachea. After the tube tip has been passed through the vocal cords, the stylet should be withdrawn a few centimeters, and without the stylet stiffening the distal tip, the tube can then be further advanced into the trachea. The large proximal stop on the GlideRite stylet allows one-handed retraction of the stylet.

Even without a stylet, during performance of intubation with video laryngoscopes the angle that the tube tip contacts the tracheal rings can occasionally prevent tracheal insertion.¹²⁻¹⁵ Some users have advocated use of a bougie, tube rotation, or "reverse loading" the tube on the stylet to address this issue.¹²⁻¹⁵ Acknowledging the independent challenge of tube advancement, the manufacturer of the GlideScope now

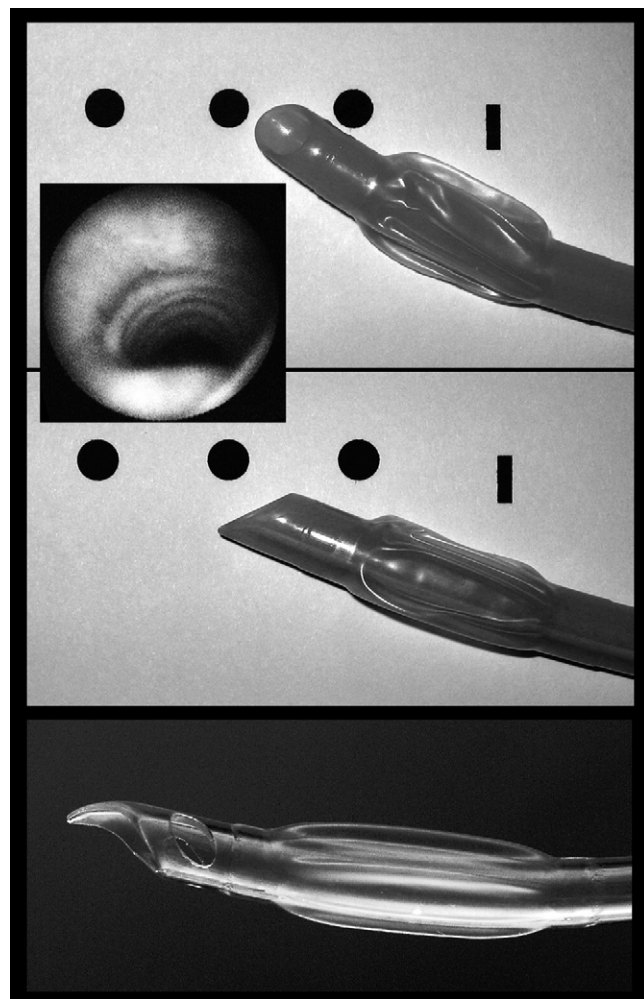


Figure 6. The top image shows a left-facing bevel of a standard endotracheal tube, with the leading edge of the tube between the first and second tracheal rings (the vocal cords are denoted by the thin vertical line; the rings, by solid dots). The drawing is from a lateral perspective of the trachea, with the round dots representing a sagittal cross-section of the tracheal rings. An inset shows the tracheal rings as they appear with a fiberoptic instrument. Rotation of the tube clockwise (middle image) drops the tip downward, disengaging it from the tracheal rings, and also lowering the trajectory of the tube. At the bottom is the symmetric, ski-tip distal tip of the Parker endotracheal tube. This tube design is also advocated by the manufacturer of the GlideScope.

advocates using a special endotracheal tube, the GlideRite tube. This tube design, manufactured for GlideScope by Parker Medical (Highlands Ranch, CO), has a symmetric tip with a ski-tip shape (Figure 6, bottom). Unlike the relatively sharp and unyielding edge of a standard endotracheal tube with a left-facing bevel, the ski-tip of the Parker design glides over the tracheal rings, allowing the tube to pass into the trachea (Figure 5).

When a standard tube with a left-facing bevel is inserted, whether during direct laryngoscopy or with an alternative

imaging device, if resistance is encountered, it is sometimes helpful to rotate the tube clockwise (Figure 6, top). By rotating the tube clockwise, the bevel rotates from facing leftward to facing upward, which lowers the leading edge of the tube and disengages the tip from interacting with the tracheal rings. It also lowers the trajectory of the tube to be more congruent with the orientation of the trachea. An alternative approach is to reverse load the endotracheal tube on the stylet, which involves mounting the tracheal tube on the rigid stylet in a direction opposite to its natural curve or alternatively reshaping a malleable stylet so that the imposed curve is opposite to its natural shape.¹⁵ When the stylet is withdrawn, the endotracheal tube will tend to descend into the trachea.

When using the video laryngoscopes and optical devices, excessive depth of insertion can have several unintended consequences:

- It reduces the visual field.
- It demands greater accuracy in the delivery of the endotracheal tube.
- It tilts the laryngeal axis upward, thereby increasing the angle of incidence between the laryngoscope blade and the trachea, making tube advancement more difficult.

Partial withdrawal of the laryngoscope blade frequently corrects these disadvantages, even though glottic exposure may be less complete.

CONCLUSION

Clinicians responsible for tracheal intubation should appreciate that the procedure is best understood when broken down into 3 components: (1) laryngeal exposure; (2) delivering the endotracheal tube to the glottic opening; and (3) advancing the tube into the trachea. Every intubation technique and device has its own optical and mechanical complexities. With direct laryngoscopy, the greatest potential challenges involve creating a direct line of sight to the target (laryngeal exposure) and delivering a tube to the glottic opening without blocking the line of sight. Tube advancement into the trachea is usually straightforward if the stylet bend angle is not too steep (<35 degrees) and the bend point is at the proximal cuff (creating a narrow long axis). Video and optical laryngoscopes can provide remarkably easy laryngeal exposure because of the positioning and location of the video camera or imaging lens. These devices are transforming airway management in many respects, both in terms of difficult airway management and education. Although they bypass the mechanics of direct laryngoscopy, all alternative devices create different potential challenges in getting the tube to the glottic opening and advancing the tube into the trachea. Sharp-angled, nonchanneled video laryngoscopes usually require stylets to aid tube delivery, but the stylet must be partially withdrawn to permit tube advancement. Tube rotation, use of a tube introducer, or using specialized endotracheal tubes may also help with tube advancement. For channeled devices, getting around the tongue is straightforward, but delivering the tube tip to the glottic

opening may require directly lifting the epiglottis or manipulating the device to alter the exiting direction of the tube tip.

Supervising editor: Kathy J. Rinnert, MD, MPH

Funding and support: By *Annals* policy, all authors are required to disclose any and all commercial, financial, and other relationships in any way related to the subject of this article that might create any potential conflict of interest. See the Manuscript Submission Agreement in this issue for examples of specific conflicts covered by this statement. The manufacturers of the devices provided Dr. Levitan with the devices. Dr. Levitan is a principal in Airway Cam Technologies, Inc., Wayne, PA, which sells a variety of airway management products, including laryngoscopes, endotracheal tubes, and rescue devices. Airway Cam is a distributor of the AirTraQ Optical Laryngoscope and Parker endotracheal tubes mentioned in this article. Dr. Cooper is a consultant for Verathon, manufacturer of the GlideScope Video Laryngoscope.

Publication dates: Received for publication March 15, 2010. Revision received April 26, 2010. Accepted for publication May 25, 2010. Available online July 31, 2010.

Reprints not available from the authors.

Address for correspondence: Richard M. Levitan, MD, Thomas Jefferson University Hospital, 11th & Walnut Street T239, Philadelphia, PA 19107; 215-955-6844, E-mail airwaycam@gmail.com.

REFERENCES

1. Levitan RM, Pisaturo JT, Kinkle WC, et al. Stylet bend angles and tracheal tube passage using a straight-to-cuff shape. *Acad Emerg Med*. 2006;13:1255-1258.
2. Cooper RM, Pacey JA, Bishop MJ, et al. Early clinical experience with a new videolaryngoscope (GlideScope) in 728 patients. *Can J Anaesth*. 2005;52:191-198.
3. Bader SO, Heitz JW, Audu PB. Tracheal intubation with the Glidescope videolaryngoscope, using a "J" shaped endotracheal tube. *Can J Anaesth*. 2006;53:634-635.
4. Maassen R, Lee R, Hermans B, et al. A comparison of three videolaryngoscopes: the Macintosh laryngoscope blade reduces, but does not replace, routine stylet use for intubation in morbidly obese patients. *Anesth Analg*. 2009;109:1560-1565.
5. Cooper RM. Complications associated with the use of the GlideScope videolaryngoscope. *Can J Anaesth*. 2007;54:54-57.
6. Williams D, Ball DR. Palatal perforation associated with McGrath videolaryngoscope. *Anaesthesia*. 2009;64:1144-1145.
7. Dhonneur G, Abdi W, Amathieu R, et al. Optimising tracheal intubation success rate using the Airtraq laryngoscope. *Anaesthesia*. 2009;64:315-319.
8. Beckmann LA, Edwards MJ, Greenland KB. Differences in two new rigid indirect laryngoscopes. *Anaesthesia*. 2008;63:1385-1386.
9. Suzuki A, Abe N, Sasakawa T, et al. Pentax-AWS (Airway Scope) and Airtraq: big difference between two similar devices. *J Anesth*. 2008;22:191-192.
10. Dimitriou VK, Zogogiannis ID, Douma AK, et al. Comparison of standard polyvinyl chloride tracheal tubes and straight reinforced tracheal tubes for tracheal intubation through different sizes of the Airtraq laryngoscope in anesthetized and paralyzed patients: a

- randomized prospective study. *Anesthesiology*. 2009;111:1265-1270.
11. Walker L, Brampton W, Halai M, et al. Randomized controlled trial of intubation with the McGrath Series 5 videolaryngoscope by inexperienced anaesthetists. *Br J Anaesth*. 2009;103:440-445.
 12. Heitz JW, Mastrando D. The use of a gum elastic bougie in combination with a videolaryngoscope [letter]. *J Clin Anesth*. 2005;17:408-409.
 13. Budde AO, Pott LM. Endotracheal tube as a guide for an Eschmann gum elastic bougie to aid tracheal intubation using the McGrath or GlideScope videolaryngoscopes. *J Clin Anesth*. 2008; 20:560.
 14. Walls RM, Samuels-Kalow M, Perkins A. A new maneuver for endotracheal tube insertion during difficult GlideScope intubation. *J Emerg Med*. 2010 Jan 23 [Epub ahead of print].
 15. Dow WA, Parsons DG. "Reverse loading" to facilitate GlideScope intubation. *Can J Anesth*. 2007;54:161-162.