
The Laryngeal Mask Airway: Its Role in the Difficult Airway

■ Stephen L. Campo, MD

■ William T. Denman, MB, ChB, FRCA

The laryngeal mask airway (LMA) is a relatively new device that was brought into clinical practice in the 1980s. It was conceived, designed, and developed between 1981 and 1988 by Dr. Archie Brain, a British anesthesiologist who felt that a component for airway management was missing. The laryngeal mask was conceived to provide the bridge between the face mask and the endotracheal tube. The concept was that this mask would fill the niche, both anatomically and physiologically, between the two. The LMA would be more invasive than a face mask but less invasive than an endotracheal tube. Although Brain originally introduced the LMA as a general airway device, he was immediately aware that it would have some use in the management of difficult airways. In his pilot study published in 1983, he reported on the successful use of the LMA in 23 patients.¹ Two of these patients had anatomy suggestive of a difficult intubation and “neither presented difficulty with regard to insertion of the LMA.” He concluded, “the LMA would appear to be of particular value where difficulty is experienced in maintaining the airway.”

The LMA proved to be a simple device that was easy to teach, and easy to learn, how to use. Multiple series in both adult patients and pediatric patients detailed the ease of its use.^{2, 3} The device quickly spread throughout the anesthesia community. It is relatively noninvasive and can be placed both rapidly and easily. Given these facts, it is not surprising that case reports detailing its successful use in difficult airways began to grow. In 1985, only 2 years after his original study, Brain reported on three cases of difficult intubation in which the LMA was successfully used.⁴ This included one patient who was unexpectedly difficult to intubate and ventilate.

The success of the LMA is probably due to two salient features: it performs adequately even when it is used poorly and allows for airway control and ventilation without affecting the function of the larynx. This

is due in part to the large area of the airway, which allows gas exchange even if airway alignment is poor. These two points make the LMA particularly useful in the management of the difficult airway.

As mentioned before, the LMA was originally conceived as a general airway device but is now considered to have an established role in the management of difficult airways. The LMA has a long clinical record of successful use in difficult airways. It has been used for a wide variety of airway problems, both in adults and children. The number of airway problems that have been overcome with the LMA are many, and examples of its use in adults and children are shown in the Table.

■ Insertion

The insertion of the LMA can be likened to the act of swallowing. This is true both in the physiological approach and the anatomical position at which the LMA resides. The standard insertion technique was designed and modified by many investigators and researchers to enable the LMA to be positioned in the hypopharynx with the minimum of effort and noxious stimuli to the patient. The LMA resides in a space that is shared by both the respiratory tract and the alimentary tract. With the patient under anesthesia, the practitioner simulates the swallowing act by flattening the mask against the hard palate and applying pressure in a centrifugal manner. The LMA is then advanced along the posterior pharyngeal wall. If the standard technique is used, the LMA is inserted blindly into the hypopharynx and the anterior structures such as the tongue, vallecula, epiglottis, and arytenoids are avoided. Since these structures are highly innervated, contact with them will likely elicit defensive mechanisms such as coughing, retching, or laryngospasm. One of the major benefits of the use of the LMA, especially in the difficult airway, is that muscle relaxants are not necessary to achieve adequate insertion and a laryngoscope is not needed for LMA insertion. Difficulty on insertion is usually at the point where the LMA is navigating the area just posterior to the tongue. If firm posterior air pressure is kept on the pharyngeal wall, this difficulty is usually overcome. In most people's experience, using the standard technique correctly results in the best conditions for insertion. It is also necessary to use the correct size LMA for the patient.

Difficult Airways Managed with the LMA

Ankylosing spondylitis	Rheumatoid arthritis
Facial burns	Obesity
Failed obstetric intubation	Neck contractures
Limited mouth opening	Motor vehicle accident
Hemifacial microsomia	Multiple difficult intubations
Percutaneous tracheostomy	Unstable neck

The LMA can be inserted in the awake patient, but it is generally easier to insert it in a patient in whom general anesthesia has been induced or topical anesthesia has been applied to the mouth and pharynx, thereby obtunding the gag and swallowing reflexes.

■ Anatomy

The LMA resides in the hypopharynx, with the anterior portion of the LMA abutting the posterior aspect of the tongue. The epiglottis rests within the bowl of the mask in an anatomical position in most situations. In children, the epiglottis is often at a greater angle to the cervical spine than in adults, and this may make it difficult to intubate the trachea in children through the LMA. The tip of the LMA abuts the cricopharyngeus in most insertions. When a fiberscope is advanced into the LMA and the aperture bars are sighted, the glottic opening is usually visible within the bowl of the LMA.

■ Cricoid Pressure and the LMA

Upon correct positioning, the tip of the LMA is usually behind the cricoid cartilage. Due to the tip of the LMA lying behind the cricoid cartilage, cricoid pressure may impede the placement of the LMA. Several large studies have shown that cricoid pressure has no effect on the placement of the LMA, and two studies have shown that LMA insertion is affected by cricoid pressure.⁵ Combining the results, it appears that LMA insertion is more likely to be successful without cricoid pressure. When inserting the LMA in a patient in whom cricoid pressure is considered necessary, the clinician must determine which factors are more important, that is, whether establishing the airway is of priority over the risk of aspiration following regurgitation.

■ Physiology

The LMA is a relatively noninvasive airway as compared to the endotracheal tube, and in most cases, the physiological disturbances following placement are minimal. Obviously, because the trachea is not intubated, there is less stimulation of the respiratory system. Studies have shown that cardiovascular perturbations are less following insertion of the LMA⁶ and that once the LMA is inserted, the anesthetic requirements for maintenance of anesthesia are less in patients with an LMA.⁷ Intermittent positive pressure ventilation is possible in most patients following insertion of

LMA. Airway pressures need to be kept below 20 cm H₂O in most patients to reduce the risk of gastric distension and to prevent leakage around the mask.

■ Aspiration

The correctly placed LMA airway tip lies against the cricopharyngeus muscle at the top of the esophagus. However, the LMA does not isolate the respiratory tract from the gastrointestinal tract. Therefore, regurgitated contents from the stomach may enter the trachea. A meta-analysis of 547 publications suggested that the incidence of aspiration with an LMA was 2/10,000 anesthetics.⁸ This compares favorably to figures using an endotracheal tube or a face mask. The risk of aspiration with the LMA should be considered the same as that for a patient-undergoing anesthesia with a face mask. In the scenario of the difficult airway, the establishment of an airway and provision of oxygen and ventilation must be weighed against the risk of aspiration. Obviously, in a hypoxic or anoxic patient, the providing of oxygen far outweighs the risk of aspiration of stomach contents.

■ The Difficult Airway

Incidence of Difficult Intubations

The incidence of difficulty in tracheal intubations occurs in 1% to 3% of patients.⁹ This incidence depends on operator experience and is highest in the obstetric population. Failed tracheal intubation varies from between 1 and 500 in the obstetrical population and 1 in 2000 in the nonobstetrical surgical population. Rose and Cohen,¹⁰ in a prospective survey of 18,500 patients, showed that 2% of patients required three or more attempts at tracheal intubation and that a failure rate of 0.3% was present when using the laryngoscope. This obviously covers a wide range of patients, and these patients are not necessarily impossible intubations but rather difficult or unexpected difficult intubations. Fortunately, the rate at which the “can’t ventilate, can’t intubate” situation arises is about 1 in 10,000 anesthetic cases.¹¹ Depending upon one’s practice, this may mean that one would only see the “can’t intubate, can’t ventilate” patient about once every 10 to 12 years of the standard attending practice. While some difficult airways might be predictable from a variety of bedside tests, the variability in predicting the difficult airway is huge, and interobserver variability is enormous. As such, it is difficult to become proficient at dealing with difficult airways unless one actively practices the management of difficult airways. It should be remembered that the failure to

manage competently the difficult airway is responsible for 30% of the deaths that are attributable to the conduct of the anesthetic.¹² When closed malpractice claims are reviewed, 85% of ventilatory-related claims involve brain damage or death. Sixty-eight percent of these are represented by inadequate ventilation (33%), esophageal intubation (18%), and difficult tracheal intubation (17%). Aspiration represents only 5% of respiratory claims and is a relatively uncommon sequela of failed or difficult intubation.¹²

The Use and Place of the LMA in the Difficult Airway

The LMA can be used to provide routine airway management during anesthesia, or it can be used to facilitate airway management during tracheal intubation. The LMA has been used in both of the above situations. The role of the LMA in the difficult airway has been extensively reviewed and some examples of its use are given in the Table.

As before, the usefulness of the LMA is predominately due to the ease and reliability with which it can be inserted. This insertion is usually accomplished at the first attempt and tissue trauma is minimal. Of note is that whether one can view the laryngeal structures is irrelevant to the placement of the LMA. In the case of a difficult face mask airway, the airway management with the LMA is usually very straightforward. Studies have shown that the LMA is superior to the face mask and oral airway in patients with normal anatomy or where oxygen saturation was the endpoint.¹³

■ Use in the Abnormal Airway

The incidence of successful LMA placement in the known difficult airway is not known, but there are over 60 case reports of the LMA being used in difficult airways.¹⁴ There have also been several uncontrolled studies that support these findings. In some studies, successful placement occurred in over 97% of patients with known or predicted difficult intubations. Langenstein¹⁵ looked at a group of patients with known abnormal airways and found LMA insertion successful in 29 of 30 cases.

LMA insertion is probably not dependent on the same factors that predict difficult intubations. In a retrospective study, it was shown that there was no correlation between Mallampati classification and ease of insertion or final fiberoptic LMA position.¹⁶ However, McCrory and Moriarty¹⁷ did find that Mallampati scoring was related to final LMA position. This conflict is not unexpected. The Mallampati score is designed to determine the probability that the laryngeal structures will be visible at laryngoscopy. The LMA position and ability to ventilate was not deter-

mined by the Mallampati score, and in all patients in whom the Mallampati score was 3, LMA insertion was accomplished on the first attempt. It has been stated that if the uvula, palate, and faucial pillars are not visible (Mallampati 4) then it will be difficult to pass the LMA around the base of the tongue. However, if the LMA is inserted correctly, the LMA is positioned entirely posteriorly and should avoid the anterior structures. When examined, the Mallampati score in effect highlights a large tongue in proportion to the mouth, which is irrelevant in most placements of the LMA. There are, however, reports in which the LMA insertion failed in patients with difficult airways. These difficult LMA insertions may have been due to several factors. Excessive extension of the neck may make the insertion of the LMA more difficult. Limited mouth opening, intraoral/pharyngeal pathology, and cricoid pressure may make placement more challenging. When the airway opening is limited, the LMA may be impossible to pass if the distance between upper and lower incisors is too small.

The LMA as a Definitive Airway

The LMA has been used in many situations of difficult airways, both anticipated and unanticipated, in which the trachea was not intubated following placement of the LMA. This has occurred in patients who are both fasted and nonfasted, children, and neonates. Having said this, clinicians must determine for themselves whether it is appropriate to use the LMA as the airway.

The LMA as an Aid to Intubation

Providing easy access to the vocal cords and trachea and allowing the ability to both monitor ventilation and provide oxygenation to the patient while attempting to intubate the trachea make the LMA a useful aid to tracheal intubation. The shape and manufacture of the LMA make access to the glottic opening easy. When using the LMA as a conduit for tracheal intubation, several factors must be considered. First, the internal diameter (ID) of an LMA tube will only accommodate a 6-mm endotracheal tube. Although this is a small tube, it is usually adequate. If a larger endotracheal tube is needed, the tube may be changed over a tube exchanger. The larger # 5 LMA will accept a 7-mm tracheal tube, and the new intubating LMA will accommodate an 8-mm endotracheal tube. Second, in patients who are tall or have a long neck, the endotracheal tube may not be long enough to pass beyond the vocal cords sufficiently to allow the inflation of the cuff. The mean distance from the mask aperture bars to the vocal cords is 3.6 cm in adults. The average endotracheal tube, when fully inserted into the LMA will be at 21 cm at the teeth. It is felt that the endotracheal tube needs to extend about 9 cm to ensure complete insertion into the trachea.¹⁸ The third issue that needs to be brought to mind

is the removal of the LMA over the laryngeal tube. This may be difficult, as extubation of the trachea may occur. This may be circumvented by the use of a tracheal tube exchange. This necessitates removing the endotracheal tube and the LMA and then using the tube exchanger as a guide to reintubate the trachea. Alternatively, the LMA can be left in the patient, the LMA cuff deflated, and the patient's trachea extubated when appropriate, taking out the endotracheal tube and LMA at the same time.

Blind Techniques

A major advantage of intubating the trachea blindly through the LMA is that the fibroscope is not needed. The converse is that it may require more time, result in trauma, or lead to an esophageal intubation. The success rates for intubating the trachea blindly through the LMA vary between 30% and 90% depending upon technique, experience and number of attempts taken, the equipment chosen, and the application of cricoid pressure.¹⁹ It has been noted that the application of cricoid pressure does decrease the success rate of blind intubation of the trachea.²⁰ Several techniques have been advanced for increasing the chances of success following a blind intubation through the LMA, for example, use head extension to increase the chance of the endotracheal tube tip entering the laryngeal vestibule and, at the point at which resistance is felt, which is the endotracheal tube contacting the anterior wall of the trachea, the head and neck are then flexed to line up the axes of the tracheal tube with the trachea. This second example is used to allow the endotracheal tube to negotiate the S-shaped route encountered when coming through the hypopharynx into the larynx and then into the trachea. Lubrication of the endotracheal tube is important and the use of a round beveled tube is beneficial. An alternative approach is to pass a stylet or bougie into the trachea. Once the guide is in the trachea, the LMA is removed and the guide is used to "railroad" the endotracheal tube into the trachea. Successful placement of the bougie can be improved by keeping the bougie in the midline and angling the tip of the bougie anteriorly. Once the laryngeal vestibule is entered, rotating the bougie through 180 degrees may facilitate the advancement of the bougie down the trachea.

Fiberoptic Techniques

The use of the fiberoptic bronchoscope through the LMA to intubate the trachea is associated with an extremely high rate of success for tracheal intubation.²¹ Following adequate and proper placement of the LMA, the glottic opening is usually available and directly in front of the aperture bars (Fig. 1). The bronchoscope is then advanced into the trachea and used as a guide for endotracheal tube insertion. One difficulty that may be encountered is downfolding of the epiglottis. In this situation, blind pas-

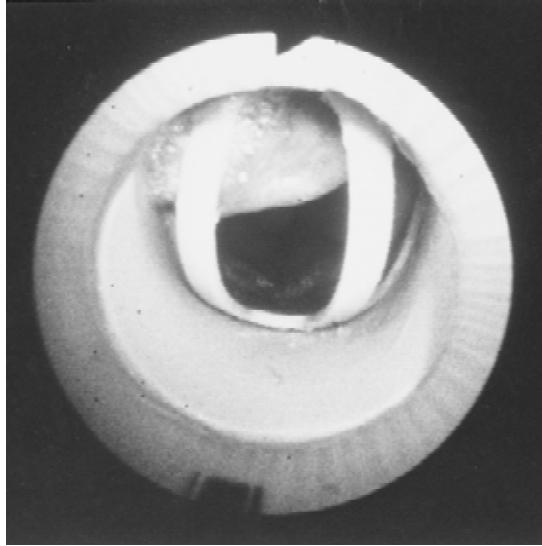


Figure 1. *Following proper placement of the laryngeal mask airway using the fiberoptic bronchoscope, the glottic opening is available and directly in front of the aperture bars.*

sage may fail but direct vision through the scope may improve success. This condition is more common in children than in adults.²² Problems may also occur when advancing the endotracheal tube, such as hanging on the aperture bars or striking the anterior wall of the trachea. Rotation of the endotracheal tube will overcome these difficulties. A sharp S-bend may be encountered also, particularly in a patient with flexion deformities, and it has been noted that some patients have such severe flexion deformities that the bronchoscope is unable to negotiate the course needed to enter the trachea.

When preparing for a fiberoptic-guided intubation, the endotracheal tube is loaded onto the bronchoscope and lubrication is applied to the bronchoscope (Fig. 2). It is necessary to become facile with the fiberoptic bronchoscope. Success rate increases with use of the bronchoscope, and this is another role the LMA has filled, namely, allowing practitioners to become proficient with the fiberoptic bronchoscope in a controlled environment where oxygenation and ventilation are well maintained.

The Intubating LMA

The first intubating LMA (Fastrach) prototype was used in 1983. It differed from the initial LMAs by having a wider, shorter, and stiffer tube. The bowl of the intubating LMA also had a raised area posteriorly to direct the tracheal tube anteriorly. The intubating LMA tube was 12 mm ID and so would except up to a 9-mm endotracheal tube. In 1995, further work was done, and using a prototype, Kapila and colleagues²³ intubated 78 patients. They found that 72% of the patients were intubated on the

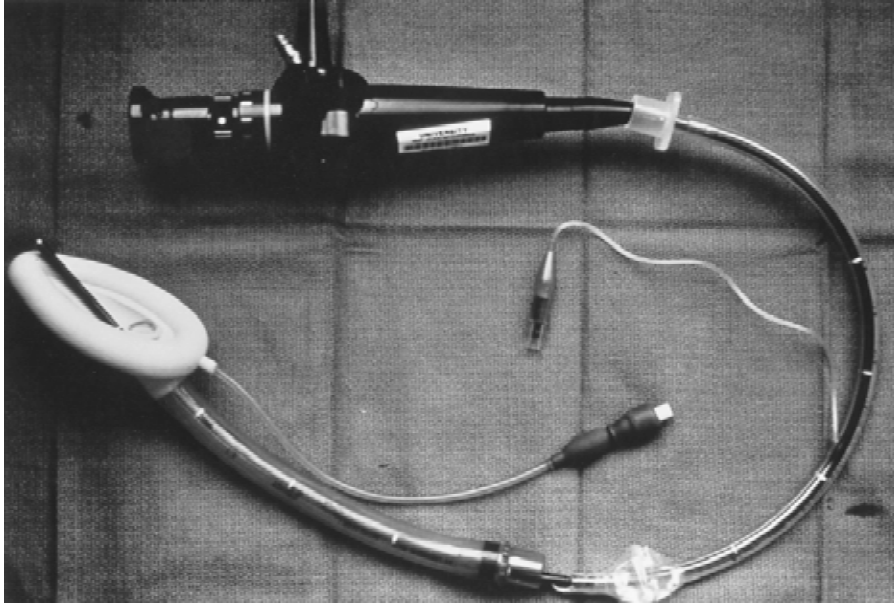


Figure 2. When preparing for a fiberoptic-guided intubation, the endotracheal tube is loaded onto the bronchoscope and lubrication is applied to the bronchoscope.

first attempt. A further 12% were intubated on the second attempt. The final version is made of a curved stainless steel airway tube with an internal diameter of 13 mm. The tube is covered in silicone and has a 15-mm connector at its end (Fig. 3). The mask portion of the intubating LMA is of very similar shape to the classical LMA. The mask aperture does not have aperture bars but rather has a flap (epiglottic lifting bar) that is used



Figure 3. The Fastrach intubating laryngeal mask airway is made of a curved stainless steel airway tube with an internal diameter of 13 mm. The tube is covered in silicone and has a 15-mm connector at its end. (Courtesy of LMA North America, Inc.)

to lift the epiglottis when the endotracheal tube is being inserted. Within the aperture, a channel exists to aim and lift the tracheal tube towards the glottic opening. The major differences, therefore, between the intubating LMA and the standard LMA are the breathing tube and a handle that allows for manipulation of the mask and the epiglottic elevating bar.

The intubating laryngeal mask may be inserted into a patient after topicalization of the mouth and pharynx or used in the patient following the induction of general anesthesia. The intubating LMA is inserted in a similar manner to the classical LMA. The insertion technique is shown in Figure 4. It is not necessary to insert the finger into the patient's mouth. Once the intubating LMA is in place, the cuff is inflated and at this point, an airway is established and confirmed. The intubating LMA may then be used as the sole airway or tracheal intubation may be accomplished.

Once the intubating LMA is inserted and the cuff inflated, the patient may be ventilated while preparing for tracheal intubation. This is accomplished by attaching the anesthetic circuit to the intubating LMA connector. This allows oxygenation and ventilation to continue during the intubation attempt. If tracheal intubation is performed, a specially designed intratracheal tube is used that has a bullnose tip on it to avoid trauma to the pharynx and trachea. Endotracheal intubation may be performed either blindly or using a fiberoptic bronchoscope. The endotracheal tube is advanced following lubrication through the intubating LMA. Slight resistance is felt as the epiglottis lifter is encountered and the tube is advanced into the trachea. Using a blind technique, the inventor found that he could intubate 98.5% of the patients on one or two attempts.²⁴ Once tracheal intubation is accomplished, the cuff on the endotracheal tube is inflated and confirmation of endotracheal tube placement is obtained. The cuff on the LMA is then deflated and an obturator device is provided whereby the intubating LMA may be removed over the endotracheal tube.

The LMA and the ASA Difficult Algorithm

Falling oxygen saturations, inability to intubate, difficulty maintaining an airway—this rare situation is one that all anesthesiologists dread. Yet, it is one that must be dealt with in an adept, expeditious, and calm manner. The only way to do this successfully is to have a well thought out plan of action. It was this realization that led to the development of a difficult airway algorithm by the American Society of Anesthesiologists (ASA). This algorithm was developed by a task force of the ASA and was published in *Anesthesiology* under practice guidelines.²⁵ The 1993 version is seen in Figure 5. When this algorithm was written, the LMA had only recently been described by Brain. It is now clear that its role in the management of a difficult airway was underappreciated. In the 1993 algorithm, the LMA was only mentioned as a footnote. In that footnote, it was considered

an option for a nonsurgical airway, along with transtracheal jet ventilation and the esophageal-tracheal combitube. This single, small-print reference to the LMA would change dramatically in just 3 years. Clinical experience with the LMA rapidly grew, as did dramatic case reports of its successful use in difficult airway scenarios. This collective clinical experience led Benumof¹⁹ to revise the algorithm in 1996. He now places the LMA in five prominent positions in the difficult airway algorithm (Fig. 6). To accentuate the LMA's role further, these five areas appear in large boxes as well as in bold print. The five places where the LMA is now considered to be essential are: (1) on the awake intubation limb of the algorithm as a conduit for fiberoptic tracheal intubation, (2) on the nonemergency pathway of the anesthetized limb as a ventilatory mechanism by which to do the case or (3) as a conduit for fiberoptic tracheal intubation, and (4) on the emergency anesthetized pathway as both a life-saving ventilatory device and (5) as a conduit for fiberoptic tracheal intubation.

Awake Intubation Limb In the known difficult airway, the safest approach is to secure the airway while the patient is awake. It is true that the LMA has rescued anesthetized patients who were impossible to ventilate or intubate, including pediatric patients. Yet to simply anesthetize patients with known difficult airways and assume the LMA will work is foolhardy. In large series of adult patients detailing LMA use, there is a low but real incidence of failure to establish an airway of 0.4% to 6.0%.¹⁹ Similar numbers have been described in pediatric surveys.² Although the failure rate in patients with known difficult airways is unknown, it is not zero. Thus, an awake intubation is still considered the safest technique. The use of an LMA as a guide to an awake intubation was first described in 1991.²⁶

LMA As an Airway in an Anesthetized Patient Who Cannot Be Intubated but Can Be Ventilated (Nonemergent Limb) In an anesthetized patient who can be ventilated but cannot be intubated, the LMA may be used as the definitive airway device. Although the LMA will not protect against aspiration, in patients in whom aspiration is not considered a risk, it can be of great use. It is clear that when faced with a patient who is anesthetized and cannot be intubated, the LMA is a reasonable alternative. In a patient at risk for aspiration who cannot be intubated, one must weigh the relative risks of continuing the anesthetic against awakening the patient and canceling the procedure.

LMA As a Conduit for Fiberoptic Intubation in an Anesthetized Patient (Nonemergent Limb) As described in the previous section, an LMA may be placed in a patient who cannot be intubated but can be ventilated. Although the LMA may provide adequate ventilation, there are some situations in which an endotracheal tube may be preferable or necessary. When high airway pressures are needed or tracheal protection with a

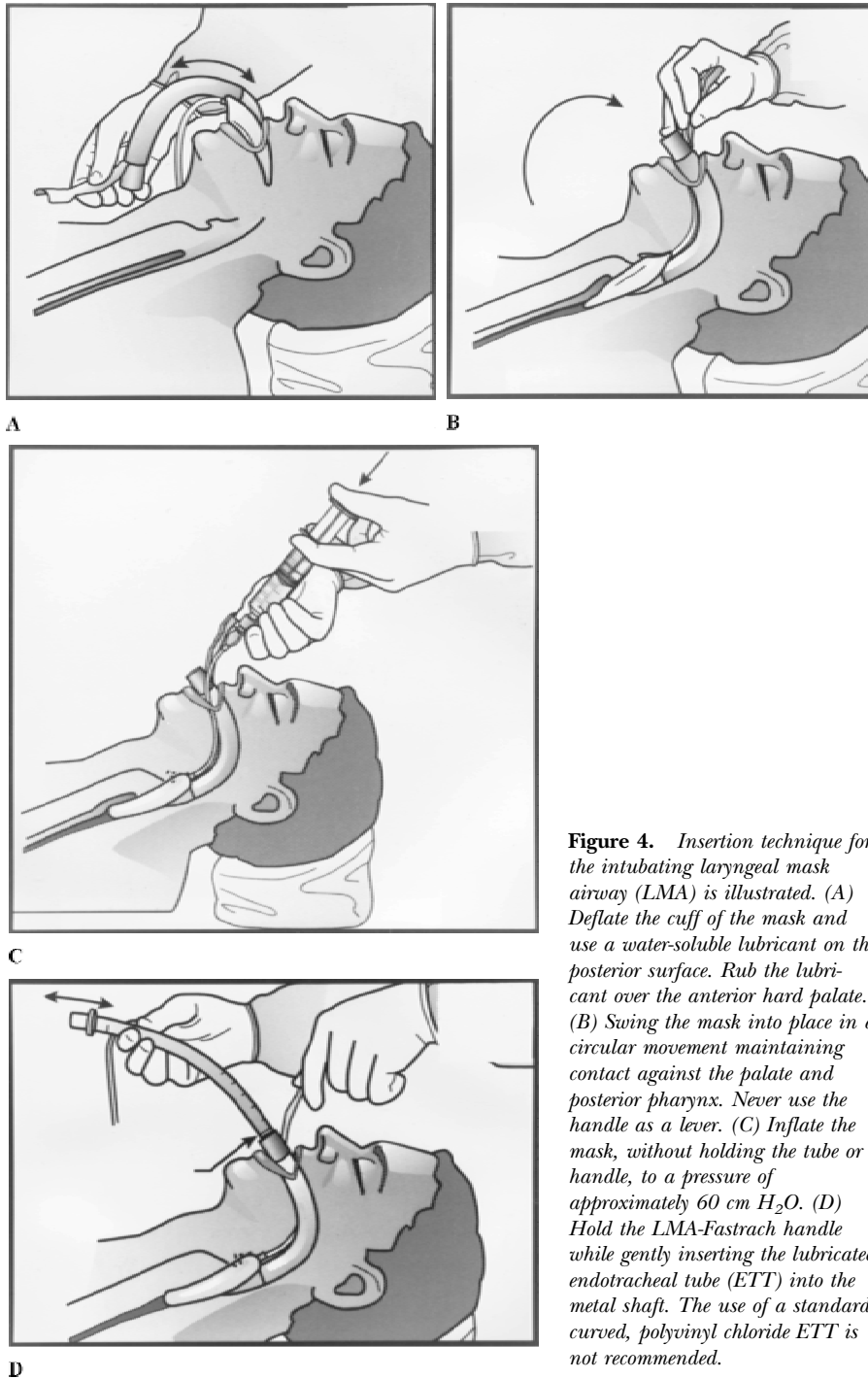


Figure 4. Insertion technique for the intubating laryngeal mask airway (LMA) is illustrated. (A) Deflate the cuff of the mask and use a water-soluble lubricant on the posterior surface. Rub the lubricant over the anterior hard palate. (B) Swing the mask into place in a circular movement maintaining contact against the palate and posterior pharynx. Never use the handle as a lever. (C) Inflate the mask, without holding the tube or handle, to a pressure of approximately 60 cm H₂O. (D) Hold the LMA-Fastrach handle while gently inserting the lubricated endotracheal tube (ETT) into the metal shaft. The use of a standard, curved, polyvinyl chloride ETT is not recommended.

(Continued)

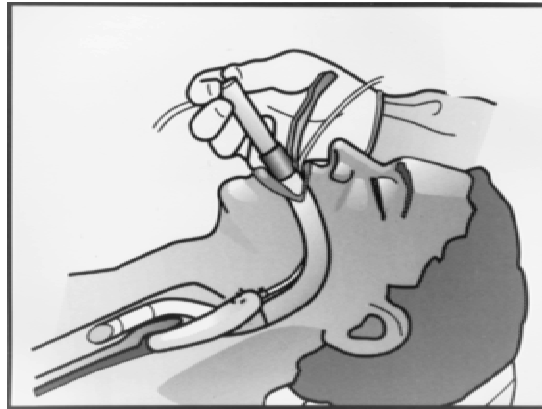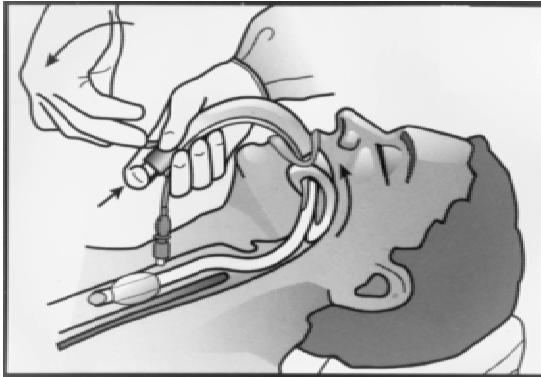
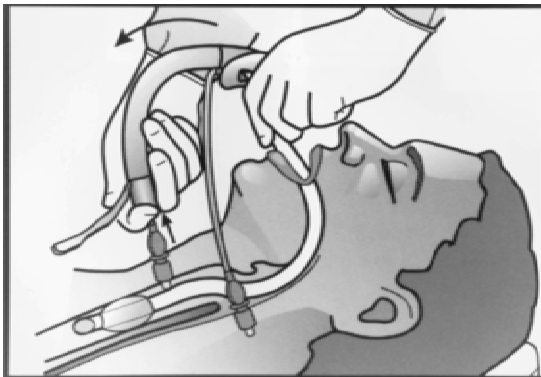
**E****F****G**

Figure 4 (cont.). (E) Advance the tube, inflate the ETT cuff, and confirm intubation. (F) Remove the connector and ease the LMA-Fastrach out by gently swinging the handle caudally. Use the stabilizing rod to keep the ETT in place while removing the LMA-Fastrach until the tube can be grasped at the level of the incisors. (G) Remove the stabilizing rod and gently unthread the inflation line and pilot balloon of the ETT. Replace the ETT connector. (Courtesy of LMA North America, Inc.)

cuffed endotracheal tube is essential, the LMA may be used to facilitate intubation.

The LMA was designed so that when it is “correctly” placed, the vocal cords would be immediately below the aperture bars. It is possible to



DIFFICULT AIRWAY ALGORITHM

1. Assess the likelihood and clinical impact of basic management problems:

- A. Difficult Intubation
- B. Difficult Ventilation
- C. Difficulty with Patient Cooperation or Consent

2. Consider the relative merits and feasibility of basic management choices:

- A. **Non-Surgical Technique for Initial Approach to Intubation** vs. **Surgical Technique for Initial Approach to Intubation**
- B. **Awake Intubation** vs. **Intubation Attempts After Induction of General Anesthesia**
- C. **Preservation of Spontaneous Ventilation** vs. **Ablation of Spontaneous Ventilation**

3. Develop primary and alternative strategies:

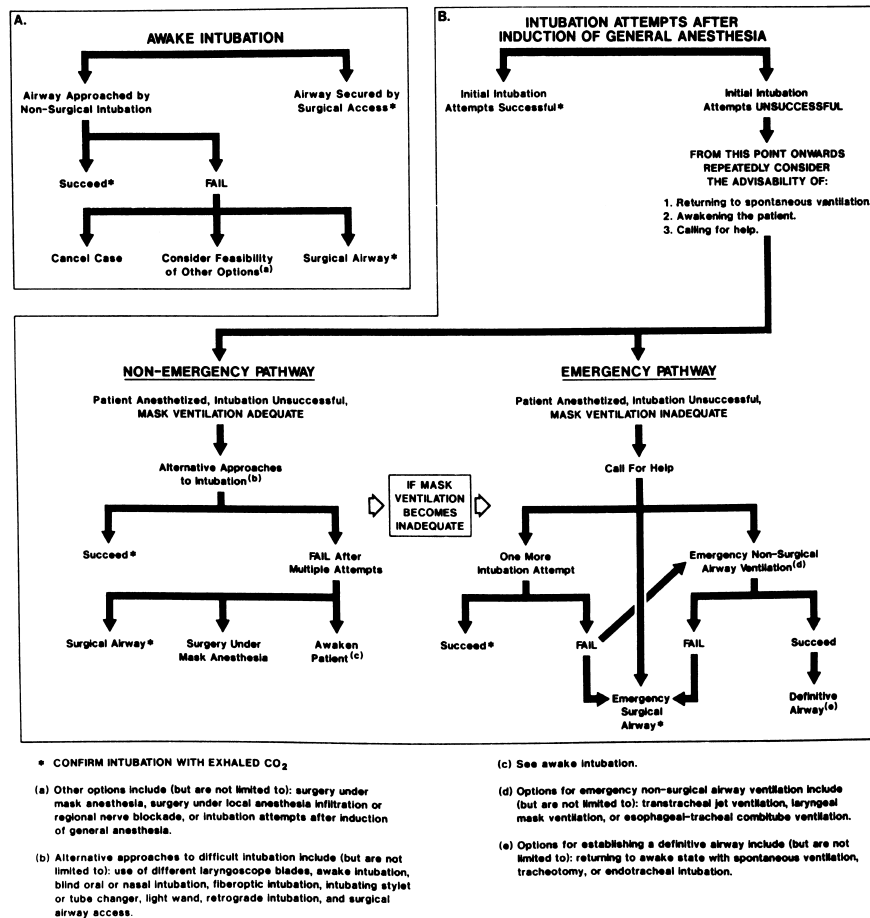


Figure 5. Flow chart shows the American Society of Anesthesiologists difficult airway algorithm of 1993.

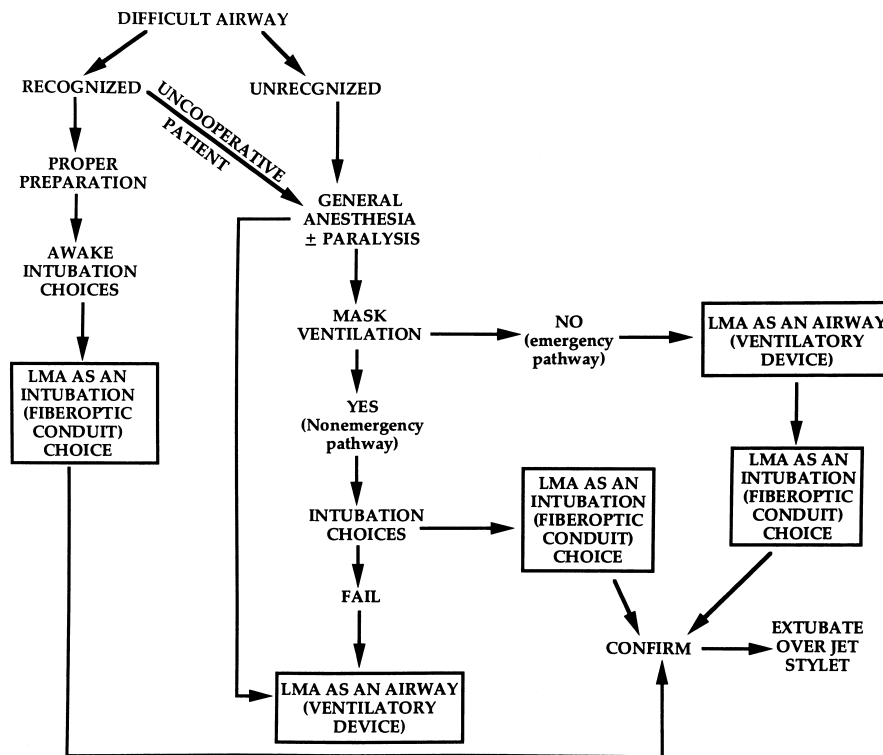


Figure 6. Flow chart shows that the laryngeal mask airway (LMA) is in five prominent positions in the American Society of Anesthesiologists difficult airway algorithm of 1996.

blindly pass an endotracheal tube through a correctly positioned LMA, as previously described. Although successful blind intubation via the LMA is possible, a fiberoptic-guided intubation may be preferable. Several series of fiberoptic bronchoscopy via functioning LMAs detail less than perfect positioning.^{27, 28} In one study, up to 51% of patients had partial obstruction, including some in whom the downfolded epiglottis blocked the view of the cords entirely.²² This may explain the failures seen in some series of blind intubations via the LMA. Those patients may have been easily intubated with a maneuverable fiberoptic scope through the LMA. Although no large series have been done comparing blind passage with fiberoptic guidance, it seems logical to conclude that direct vision via a fiberoptic scope will improve intubation rates.

LMA As an Emergency Airway (Anesthetized Emergency Limb) In the unexpected emergency in which one cannot ventilate or intubate the patient, a LMA is one of four options. The other three options include the tracheal esophageal Combitube, transtracheal jet ventilation, and creation of a surgical airway. Given the lack of familiarity with combitubes and the

potential complications with transtracheal jet ventilation, it seems rational that an LMA should be attempted first. There have been multiple reports of the successful use of the LMA in this situation, as described earlier. Although there have been no reports of failure of the LMA in this situation, one must be ready to perform transtracheal jet ventilation and/or establish a surgical airway if the LMA fails.

Use of the LMA As a Conduit for Intubation (Anesthetized Emergency Limb) This is the same situation as described above. However, once the airway is emergently secured with the LMA, it may be preferable to intubate the patient. At this point, the airway should be secure with adequate ventilation and oxygenation via the LMA. If endotracheal intubation is preferred, it should be able to be performed calmly, as previously described.

■ Conclusion

No large controlled studies have been done comparing the LMA with other emergency airway devices. Nor is it likely that any ever will be. The LMA's clinical record alone has proven it to be an invaluable device. The ability to provide safe anesthesia care was greatly increased with the introduction of the LMA. What is clear from multiple reports is that it has rescued many patients from a dire situation involving poor airways. This is true in all age groups from premature infants to elderly adults. Its excellent clinical record and simplicity demand its inclusion in any approach to the difficult airway as detailed by Benumof.¹⁹ It has improved our ability to handle difficult airways in unmeasurable ways and should be present in all anesthetizing locations.

■ References

1. Brain AJ. The laryngeal mask airway—a new concept in airway management. *Br J Anaesth* 1983;55:801
2. Mason DG, Bingham RM. The laryngeal mask airway in children. *Anaesthesia* 1990;45:760–763
3. Verghese C, Brimacombe JR. Survey of laryngeal mask airway usage in 11,910 patients: safety and efficacy for conventional and nonconventional usage. *Anesth Analg* 1996;82:129–133
4. Brain AJ. Three cases of difficult intubation overcome by the laryngeal mask airway. *Anaesthesia* 1985;40:353–355
5. Brimacombe AJ, Berry AM, Brain AJ. The laryngeal mask airway. *Anesth Clin North America* 1995;13:411–437
6. Wilson IG, Fell D, Robinson SL, Smith G. Cardiovascular responses to insertion of the laryngeal mask. *Anaesthesia* 1992;47:300–302
7. Wilkins CJ, Cramp PG, Staples J, Stevens WC. Comparison of the anesthetic require-

- ment for tolerance of laryngeal mask airway and endotracheal tube. *Anesth Analg* 1992;75:794-797
8. Brimacombe J, Berry A. The incidence of aspiration associated with the laryngeal mask airway—a meta-analysis of published literature. *J Clin Anesth* 1995;7:297-305
 9. Latto IP. Management of difficult intubation. In: Latto IP, Rosen M, eds. *Difficulties in tracheal intubation*. London: Bailliere Tindall, 1987:99-141
 10. Rose DK, Cohen MM. The airway: problems and predictions in 18,500 patients. *Can J Anaesth* 1994;41:372-383
 11. Benumof JL, Scheller MS. The importance of transtracheal jet ventilation in the management of the difficult airway. *Anesthesiology* 1989;71:769-778
 12. Caplan RA, Posner KL, Ward RJ, Cheney FW. Adverse respiratory events in anesthesia: a closed claims analysis. *Anesthesiology* 1990;72:828-833
 13. Smith I, White PF. Use of the laryngeal mask airway as an alternative to a face mask during outpatient arthroscopy. *Anesthesiology* 1992;77:850-855
 14. Brimacombe JR, Brain AJ. *The laryngeal mask airway: a review and practical guide*. London: Saunders, 1997:180
 15. Langenstein H. Die Kehlkopfmaske bei schwieriger Intubation. *Anaesthetist* 1995;44:712-718
 16. Brimacombe J, Berry A. Mallampatti classification and laryngeal mask insertion. *Anaesthesia* 1993;48:347
 17. McCrory CR, Moriarty D. Laryngeal mask airway positioning is related to Mallampatti grading in adults. *Anesth Analg* 1995;81:1001-1004
 18. Asai T, Latto IP, Vaughan RS. The distance between the grille of the laryngeal mask airway and the cords: is conventional intubation through the laryngeal mask safe? *Anaesthesia* 1993;48:667-669
 19. Bemunof AJ. Laryngeal mask airway and the ASA difficult airway algorithm. *Anesthesiology* 1996;84:686-699
 20. Heath ML, Allagain J. Intubation through the laryngeal mask—a technique for unexpected difficult intubation. *Anaesthesia* 1991;46:545-548
 21. Kadota Y, Oda T, Yoshimura N. Application of a laryngeal mask to a fiberoptic bronchoscope-aided tracheal intubation. *J Clin Anesth* 1992;4:503-504
 22. Rowbottom SJ, Simpson DL, Grubb D. The laryngeal mask airway in children: a fiberoptic assessment of positioning. *Anaesthesia* 1991;46:489-491
 23. Kapila A, Addy EV, Verghese C, Brain AIJ. Intubating laryngeal mask airway: a preliminary assessment of performance. *Br J Anaesth* 1995;75:228P-229P (abstract)
 24. Brain AIJ, Verghese C, Addy EV, et al. The intubating laryngeal mask. II: a preliminary clinical report of a new means of intubating the trachea. *Br J Anaesth* 1997;79:704-709
 25. Practice guidelines for management of the difficult airway. *Anesthesiology* 1993;78:597-602
 26. McCrerrick A, Pracilio A. Awake intubation: a new technique. *Anaesthesia* 1991;46:661-663
 27. Bandla HPR, Smith DE, Kiernan. Laryngeal mask airway facilitated fiberoptic bronchoscopy in infants. *Can J Anaesth* 1997;44:1242-1247
 28. Dubreuil M, Ecoffey C. Laryngeal mask guided tracheal intubation in paediatric anaesthesia. *Paediatr Anaesth* 1992;3:344