Anaesthesia
Journal of the Association of Anaesthetists of Great Britain and Ireland

Anaesthesia, 2009, **64**, pages 1337–1341 doi:10.1111/j.1365-2044.2009.06075.x

Evaluation of the GlideScope® for tracheal intubation in patients with cervical spine immobilisation by a semi-rigid collar

I. Bathory,[1] P. Frascarolo,[2] C. Kern[3] and P. Schoettker[4]

1 Staff Anaesthetist, 2 Biologist and Statistician, 3 Senior Consultant, 4 Consultant, Anaesthesiology Department, University Hospital Center and University of Lausanne, Lausanne, Switzerland

Summary

Application of cervical collars may reduce cervical spine movements but render tracheal intubation with a standard laryngoscope difficult if not impossible. We hypothesised that despite the presence of a Philadelphia Patriot® cervical collar and with the patient's head taped to the trolley, tracheal intubation would be possible in 50 adult patients using the GlideScope® and its dedicated stylet. Laryngoscopy was attempted using a Macintosh laryngoscope with a size 4 blade, and the modified Cormack–Lehane grade was scored. Subsequently, laryngoscopy with the GlideScope was graded and followed by tracheal intubation. All patients' tracheas were successfully intubated with the GlideScope. The median (IQR) intubation time was 50 s (43–61 s). The modified Cormack–Lehane grade was 3 or 4 at direct laryngoscopy. It was significantly reduced with the GlideScope ($p < 0.0001$), reaching grade 2a in most patients. Tracheal intubation in patients wearing a semi-rigid collar and having their head taped to the trolley is possible with the help of the GlideScope.

Correspondence to: Istvan Bathory
E-mail: Istvan.Bathory@chuv.ch
Accepted: 16 July 2009

In patients with cervical spine injury, securing the airway while adequately immobilising the cervical spine in order to avoid secondary neurological damage is challenging [1]. The application of a cervical collar, as advised by ATLS® teaching [1], may reduce cervical spine movement but renders tracheal intubation with a standard laryngoscope more difficult if not impossible, due to a limited mouth opening [2] and impaired glottic visualisation [3]. Awake tracheal intubation over a flexible bronchoscope is often preferred in elective procedures, but this technique is time consuming, needs expertise, and is associated with morbidity [4]. Due to these problems, when urgent tracheal intubation is required in patients with potentially unstable cervical spines, direct laryngoscopy with manual in-line stabilisation [5] after removal of the collar's anterior portion is advised and most commonly performed. Compared with the awake-fibreoptic technique, this procedure is quicker, less affected by secretions, blood or vomitus present in the airway and does not require patient collaboration. However, there is no evidence of benefit from using this technique over others [6]. As a matter of fact, studies have shown that impaired glottic visualisation and secondary increases in pressure application with manual in-line stabilisation during laryngoscopy have the potential to increase pathological cranio-cervical motion [6, 7], especially subluxation at the site of complete ligamentous disruption [8]. In addition, manual in-line stabilisation can worsen intubating conditions, therefore increasing the likelihood of failed intubation and hypoxic events [6].

A number of devices have been developed to facilitate intubation in patients with a difficult airway. Several studies report their use in patients with simulated cervical spine immobilisation by manual in-line stabilisation [9, 10]. Indirect videolaryngoscopy using the GlideScope® (Verathon Medical Inc., Bothell, WA, USA, formerly Saturn Biomedical Systems Inc., Burnaby, BC, Canada) [11, 12] has been described as one technique

with advantages such as ease of use and reduced intubation time [13], improved intubating conditions [14, 15], reduced cervical spine motion [16], and reduction of forces applied during intubation [6, 17].

We hypothesised that despite the presence of a semi-rigid cervical collar and with the patient's head taped to the trolley, we would be able to intubate all patients' tracheas using the GlideScope and its dedicated stylet.

Methods

After approval from the Human Research Committee of the University of Lausanne Medical School, informed written consent was obtained from 50 adult patients of ASA physical status 1 or 2 scheduled for elective surgical procedures requiring tracheal intubation. Exclusion criteria were: body mass index (BMI) > 35 $kg.m^{-2}$, previous difficult intubation, previous ear–nose–throat surgery or radiotherapy, gastro-oesophageal reflux or dental instability. Pre-operative evaluation and anaesthesia were provided by the anaesthetist in charge of the patient, in accordance with the standard practice of our department.

Maximal mouth opening (inter-incisor distance), neck circumference (measured at the level of the thyroid cartilage) and thyromental distance were measured while the patients were awake. A standard tracheal tube (7.5 mm internal diameter for men and 6.5 mm for women) with the dedicated preformed GlideScope stylet was prepared. After facemask pre-oxygenation with tidal volume breathing of 100% oxygen at 8 $l.min^{-1}$ for 3–5 min in order to reach an end-expiratory oxygen concentration > 80%, anaesthesia was induced by administering propofol (1.5–2.5 $mg.kg^{-1}$) and neuromuscular blockade obtained with rocuronium (0.6 $mg.kg^{-1}$). Analgesia was provided with fentanyl (2 $\mu g.kg^{-1}$). When the train-of-four response was zero at the ulnar nerve, the neck was immobilised with an appropriately sized semi-rigid Philadelphia Patriot® cervical collar (Philadelphia Cervical Collar Co., Thorofare, NJ, USA), according to the manufacturer's instructions [18]. The head was taped to the trolley (Fig. 1) in order to limit movements during intubation procedure according to ATLS guidelines [1]. The maximal mouth opening was recorded again. Laryngoscopy was attempted using a Macintosh laryngoscope with a size 4 blade and the modified Cormack–Lehane grade was noted [19]. Next, laryngoscopy with the GlideScope was performed, the modified Cormack–Lehane grade was recorded and the patient's trachea was intubated. All 50 patients' tracheas were intubated by the same experienced anaesthetist, familiar with the device. A timer was started when the intubating anaesthetist took the GlideScope and stopped when the tube was confirmed to be in the trachea by observation of the end-expiratory CO_2 curve on capnography. Oxygen saturation (S_pO_2) was noted at the end of pre-oxygenation and after intubation before the patient was connected to the ventilator. Unconsciousness was maintained with repeated propofol boluses if necessary.

Figure 1 Picture showing the patients' positioning and neck immobilisation. Picture taken with the patient's permission.

Tracheal intubation was considered a failure if it could not be accomplished within three attempts or 3 min, and in the event of desaturation (S_pO_2 < 95%). If intubation failed, the procedure was interrupted, the semi-rigid collar was removed, facemask ventilation was provided and the trachea was subsequently intubated with the GlideScope.

Each intubation procedure with the GlideScope was recorded (Pinnacle Video Transfer®, Pinnacle Systems, Inc., Mountain View, CA, USA). After the procedure, laryngeal views were independently evaluated and scored separately by the two principal investigators (IB and PS). In case of discrepancies, the third investigator (CK) was consulted.

The primary endpoint was the overall intubation success rate using the GlideScope in patients wearing a semi-rigid collar and with their head taped to the trolley. Secondary endpoints included the modified Cormack–Lehane grade at direct laryngoscopy and videolaryngoscopy (using the GlideScope), intubation time, the number of attempts and optimisation manoeuvres required (laryngeal pressure) [20], the Intubation Difficulty Scale (IDS) [20], a subjective assessment of ease of intubation, arterial oxygen saturation before and after the procedure, as well as lip or dental injuries assessed after the procedure and at the postoperative visit.

Statistical analysis

Statistical tests used were median or Chi-square when appropriate. Data were analysed using the JMP 6 statistical package (SAS Institute Inc., Cary, NC, USA).

Results

The characteristics of the 50 patients as well as morphologic factors predicting a difficult airway are summarised in Table 1. The cervical collar was sized as 'short' in 19, 'regular' in 26 and 'tall' in 5 patients.

Maximal mouth opening was significantly reduced once the cervical collar was applied; from a median (IQR) of 4.5 cm [4.5–5.0] cm to 2.0 cm [1.8–2.0] cm ($p < 0.0001$).

The modified Cormack–Lehane grade was always 3 or 4 at direct laryngoscopy. It was significantly improved with the GlideScope ($p < 0.0001$), reaching grade 2a in most patients (Table 2). There was no disagreement over the score of laryngeal views.

All patients' tracheas were successfully intubated with the GlideScope and its dedicated stylet.

The median (IQR) intubation time was 50 s (43–61) s (Fig. 2). The tracheas of 37 (74%) patients were intubated within 60 s. In one patient, prolonged intubation (119 s) was due to difficult blade insertion and macroglossia; in another (intubation time 172 s), voluminous arytenoids rendered the intubation difficult. Forty-eight patient's tracheas were intubated at the first attempt; two patients required two attempts. In 11 cases optimisation manoeuvres were necessary. In all patients, the IDS was ≤ 5 (slight difficulty). The subjective assessment of the intubation was easy in 34/50, intermediary in 12/50 and difficult in 4/50 cases. No episodes of desaturation were reported; median (IQR) S_pO_2 after the intubation procedure was 99% (98%–99%). No damage to the teeth or lips of the patients was documented.

Table 1 Patients' characteristics and morphological factors predicting difficult airway. Data are shown as mean (SD) unless otherwise indicated.

Age; years	48.0 (15.6)
Male/female	27/23
ASA (I/II)	4/46
Weight; kg	75.6 (15.4)
Height; cm	171 (9)
Body mass index; kg.m^{-2}	25.7 (4.2)
Mallampati score (1/2/3)	25/23/2
Thyromental distance; cm	7.0 (0.9)
Neck circumference; cm	39.3 (4.7)

Table 2 Laryngeal view at direct and indirect laryngoscopy. Data are shown as number of patients (proportion).

Modified Cormack–Lehane grade	Macintosh	GlideScope®
1	–	4 (8%)
2a	–	43 (86%)
2b	–	3 (6%)
3	24 (48%)	–
4	26 (52%)	–

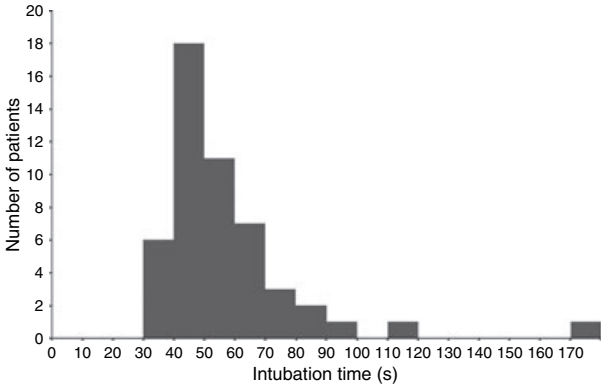

Figure 2 Distribution of intubation times.

Discussion

In this group of patients wearing a semi-rigid collar and with their head taped to the trolley, the GlideScope allowed tracheal intubation in all patients. The modified Cormack–Lehane grade was decreased significantly in all patients when the GlideScope was used.

To our knowledge, this is the first study reporting the feasibility of tracheal intubation using the GlideScope while a cervical collar is applied and the head is taped to the trolley. Our data are in agreement with a preliminary report by Agro et al. [21] showing that the GlideScope provided adequate vision of the glottis to allow intubation in 15 patients wearing an unspecified cervical collar. In their report, neither mouth opening, the ease of intubations, nor the taping of the patient's head to the trolley were reported.

By applying a cervical collar, mouth opening was decreased to a median value of 20 mm in our study. This is smaller than reported by Goutcher & Lochhead [2]. All our patients had their head taped to the trolley in order to limit potential movement during the intubation procedure as much as possible in accordance to the ATLS guidelines [1]. The cervical collar was applied in a strict way in all cases by the same experienced provider. This might explain the high number of modified Cormack–Lehane grade-4 views at direct laryngoscopy (52%). Nevertheless, we achieved a 100% success rate of intubation with no clinically relevant injuries, such as damage to the lips, teeth, gums or oropharynx, within a median of 50 s. Komatsu et al. described success rates of 100% using the Airway Scope (Pentax, Tokyo, Japan) vs 90% with a gum elastic bougie [22], and 98% with the Airway Scope vs 96% with StyletScope (Nihon Kohden

Corporation, Tokyo, Japan) [23]. The high intubation success rates with the Airway Scope were associated with mean intubation times of 34 and 32 s, shorter than our results. This might be explained by the large number of high modified Cormack–Lehane grade views at direct laryngoscopy in our study. No correlation between Airway Scope efficacy and modified Cormack–Lehane laryngeal view scores were obtained in these previous studies. No grade-4 views were observed in the first study [22] with only four grade-4 views (8%) in the second [23], thus prohibiting evaluation of these devices under such conditions. The small number of modified Cormack–Lehane grade-4 views may be related to differences in the collars that were used or how they were positioned, even though the mouth opening of these patients was similar to those that we measured in our patients. The Airway Scope was also associated with a number of lip injuries. Regarding the StyletScope; oesophageal intubations were reported as was the obstruction of view due to blood or secretions, suggesting that the utility of this device may be limited in a trauma situation.

Among the different devices studied to facilitate intubation in patients wearing a cervical collar, the intubating laryngeal mask airway has shown various success rates for achieving intubation, ranging from 20 to 100% [24–27]. Differences in methodology among the studies and variability of the type of the cervical collar used may explain these differences; in addition, the intubation remains 'blind', with the risk of injury during the intubation procedure or accidental oesophageal intubation [28].

The GlideScope has been described as a device that is easy to use, resulting in a high success rate of intubation. In our study, the GlideScope operator was an experienced anaesthetist familiar with its usage. However, before this study, he had not undertaken any intubations in patients whose cervical spines were immobilised using a cervical collar. Interestingly, there was no evidence of a learning curve in this particular setting, as the first ten and last ten intubations required similar amounts of time. In our opinion, the lack of a learning effect under these difficult intubating conditions confirms that the GlideScope is relatively easy to use [13].

The current study has some limitations. First, the most appropriate technique for performing tracheal intubation in patients with cervical spine injury continues to be debated. There are no clinical outcome data suggesting better neurological outcomes with any particular technique [29]. The risk of cervical cord injury would perhaps be reduced if removal of the collar could be avoided when securing the airway. However, there are no data supporting this hypothesis. Second, the GlideScope blade needed to be introduced and removed with extreme caution because of the small mouth opening. In many patients, the mouth opening was close to the size of the GlideScope blade itself. The risk of injury is therefore increased with this method, even though our study identified no injuries to the lips or dentition. Third, the dedicated GlideScope stylet needed to be removed resulting in potentially longer intubation times and additional hands necessary for the procedure. Fourth, our study was not randomised because no intubation was performed using direct laryngoscopy. As shown previously [3, 30], our study showed that the application of a cervical collar was associated with modified Cormack–Lehane grade-3 or -4 views. Nolan & Wilson reported that the success rate of intubation with direct laryngoscopy using a Macintosh blade was 62% when Cormack–Lehane grade-3 or -4 views were generated [7]; we did not undertake intubation using this modality in our study as it was considered inappropriate given the low success rate of this technique. Therefore there was no control group for intubation. Fifth, no patient studied had a cervical spine injury, which could have altered the intubation conditions due to oedema or modified anatomy. Sixth, the direct laryngoscopy was evaluated by a single attempt in order to reduce the risk of trauma, and a possible bias might be present as all procedures were performed by the same investigator.

In conclusion, tracheal intubation in patients having their cervical spine immobilised by a semi-rigid collar and taping their head to the trolley is possible with the help of the GlideScope without clinically relevant injuries. The modified Cormack–Lehane grades are improved significantly with this device. The high intubation success rate supports the promising role of the GlideScope for patients requiring cervical spine immobilisation, but should be reassessed in the emergency setting initially, and under controlled circumstances using experienced operators.

Acknowledgements

The authors thank Luzius A. Steiner, MD, PhD, Anaesthesiology Department, University Hospital Centre and University of Lausanne, 1011 Lausanne, Switzerland, for his valuable help and comments in reviewing the manuscript.

References

1 American College of Surgeons. *Advanced Trauma Life Support*. 2008: 157–69, Chicago, Il: ISBN 978-1-880696-31-6.

2 Goutcher CM, Lochhead V. Reduction in mouth opening with semi-rigid cervical collars. *British Journal of Anaesthesia* 2005; **95**: 344–8.

3 Heath KJ. The effect of laryngoscopy of different cervical spine immobilisation techniques. *Anaesthesia* 1994; **49**: 843–5.
4 Peterson GN, Domino KB, Caplan RA, Posner KL, Lee LA, Cheney FW. Management of the difficult airway: a closed claims analysis. *Anesthesiology* 2005; **103**: 33–9.
5 Manoach S, Paladino L. Manual in-line stabilization for acute airway management of suspected cervical spine injury: historical review and current questions. *Annals of Emergency Medicine* 2007; **50**: 236–45.
6 Santoni BG, Hindman BJ, Puttlitz CM, et al. Manual in-line stabilization increases pressures applied by the laryngoscope blade during direct laryngoscopy and orotracheal intubation. *Anesthesiology* 2009; **110**: 24–31.
7 Nolan JP, Wilson ME. Orotracheal intubation in patients with potential cervical spine injuries. An indication for the gum elastic bougie. *Anaesthesia* 1993; **48**: 630–3.
8 Lennarson PJ, Smith DW, Sawin PD, Todd MM, Sato Y, Traynelis VC. Cervical spinal motion during intubation: efficacy of stabilization maneuvers in the setting of complete segmental instability. *Journal of Neurosurgery* 2001; **94**: 265–70.
9 Maharaj CH, Buckley E, Harte BH, Laffey JG. Endotracheal intubation in patients with cervical spine immobilization: a comparison of macintosh and airtraq laryngoscopes. *Anesthesiology* 2007; **107**: 53–9.
10 Malik MA, Maharaj CH, Harte BH, Laffey JG. Comparison of Macintosh, Truview EVO2, Glidescope, and Airwayscope laryngoscope use in patients with cervical spine immobilization. *British Journal of Anaesthesia* 2008; **101**: 723–30.
11 Cooper RM. Use of a new videolaryngoscope (GlideScope) in the management of a difficult airway. *Canadian Journal of Anaesthesia* 2003; **50**: 611–13.
12 Lim Y, Lim TJ, Liu EH. Ease of intubation with the GlideScope or Macintosh laryngoscope by inexperienced operators in simulated difficult airways. *Canadian Journal of Anaesthesia* 2004; **51**: 641–2.
13 Nouruzi-Sedeh P, Schumann M, Groeben H. Laryngoscopy via Macintosh blade versus GlideScope: success rate and time for endotracheal intubation in untrained medical personnel. *Anesthesiology* 2009; **110**: 32–7.
14 Sun DA, Warriner CB, Parsons DG, Klein R, Umedaly HS, Moult M. The GlideScope video laryngoscope: randomized clinical trial in 200 patients. *British Journal of Anaesthesia* 2005; **94**: 381–4.
15 Cooper RM, Pacey JA, Bishop MJ, McCluskey SA. Early clinical experience with a new videolaryngoscope (GlideScope) in 728 patients. *Canadian Journal of Anaesthesia* 2005; **52**: 191–8.
16 Turkstra TP, Craen RA, Pelz DM, Gelb AW. Cervical spine motion: a fluoroscopic comparison during intubation with lighted stylet, GlideScope, and Macintosh laryngoscope. *Anesthesia and Analgesia* 2005; **101**: 910–15, table of contents.
17 Lee RA, van Zundert AA, Maassen RL, et al. Forces applied to the maxillary incisors during video-assisted intubation. *Anesthesia & Analgesia* 2009; **108**: 187–91.
18 Tescher AN, Rindflesch AB, Youdas JW, et al. Range-of-motion restriction and craniofacial tissue-interface pressure from four cervical collars. *Journal of Trauma* 2007; **63**: 1120–6.
19 Yentis SM, Lee DJ. Evaluation of an improved scoring system for the grading of direct laryngoscopy. *Anaesthesia* 1998; **53**: 1041–4.
20 Adnet F, Borron SW, Racine SX, et al. The intubation difficulty scale (IDS): proposal and evaluation of a new score characterizing the complexity of endotracheal intubation. *Anesthesiology* 1997; **87**: 1290–7.
21 Agro F, Barzoi G, Montecchia F. Tracheal intubation using a Macintosh laryngoscope or a GlideScope in 15 patients with cervical spine immobilization. *British Journal of Anaesthesia* 2003; **90**: 705–6.
22 Komatsu R, Kamata K, Hoshi I, Sessler DI, Ozaki M. Airway scope and gum elastic bougie with Macintosh laryngoscope for tracheal intubation in patients with simulated restricted neck mobility. *British Journal of Anaesthesia* 2008; **101**: 863–9.
23 Komatsu R, Kamata K, Hamada K, Sessler DI, Ozaki M. Airway scope and StyletScope for tracheal intubation in a simulated difficult airway. *Anesthesia & Analgesia* 2009; **108**: 273–9.
24 Komatsu R, Nagata O, Sessler DI, Ozaki M. The intubating laryngeal mask airway facilitates tracheal intubation in the lateral position. *Anesthesia & Analgesia* 2004; **98**: 858–61.
25 Wakeling HG, Nightingale J. The intubating laryngeal mask airway does not facilitate tracheal intubation in the presence of a neck collar in simulated trauma. *British Journal of Anaesthesia* 2000; **84**: 254–6.
26 Ferson DZ, Rosenblatt WH, Johansen MJ, Osborn I, Ovassapian A. Use of the intubating LMA-Fastrach in 254 patients with difficult-to-manage airways. *Anesthesiology* 2001; **95**: 1175–81.
27 Moller F, Andres AH, Langenstein H. Intubating laryngeal mask airway (ILMA) seems to be an ideal device for blind intubation in case of immobile spine. *British Journal of Anaesthesia* 2000; **85**: 493–5.
28 Dimitriou V, Voyagis GS. Blind intubation via the ILMA: what about accidental oesophageal intubation? *British Journal of Anaesthesia* 1999; **82**: 478–9.
29 Crosby ET. Airway management in adults after cervical spine trauma. *Anesthesiology* 2006; **104**: 1293–318.
30 MacQuarrie K, Hung OR, Law JA. Tracheal intubation using Bullard laryngoscope for patients with a simulated difficult airway. *Canadian Journal of Anaesthesia* 1999; **46**: 760–5.