



APPARATUS

Optimising tracheal intubation success rate using the Airtraq laryngoscope

G. Dhonneur,¹ W. Abdi,² R. Amathieu,² S. Ndoko² and L. Tual²

1 Professor, 2 Staff, Department of Anaesthesia and Intensive Care Medicine, Jean Verdier University Hospital of Paris (APHP), 93143 Bondy, France

Summary

In this study we have used a video-recording, retrospective analysis technique to evaluate the influence of the Airtraq™ laryngoscope manipulations and the resulting changes in position of the glottic opening and inter-arytenoids cleft, on the success rate of tracheal intubation. The video recordings of the internal views of 109 tracheal intubation attempts, in 50 anaesthetised patients were analysed. We demonstrated that successful tracheal intubation using the Airtraq laryngoscope require the glottic opening to be centred in the view, and positioning the inter-arytenoid cleft medially below the horizontal line in the centre of the view. We also demonstrated that repositioning of the Airtraq laryngoscope following a failed tracheal intubation attempt required the performance of a standard series of manoeuvres.

Correspondence to: Prof. Gilles Dhonneur

E-mail: gilles.dhonneur@jvr.aphp.fr

Accepted: 27 September 2008

The Airtraq™ laryngoscope (Fannin (UK) Ltd, Calcot, Reading, UK) is a novel, single use, optical laryngoscope which has been shown to improve the ease of intubation in patients with normal and difficult airways [1–3]. Although, the Airtraq laryngoscope produces a reduction in the time required for tracheal intubation in most patients with difficult airways, tracheal intubation on the first attempt, may not always be successful [4, 5]. In obese patients a clear view of the glottic opening can rapidly be obtained following insertion. However, tracheal intubation, may fail, requiring repositioning of the Airtraq laryngoscope in the pharynx prior to a further intubation attempt subsequently being successful. The manipulations frequently required are a lowering of the position of the glottis within the view.

To investigate this, we analysed the influence of the position of the glottic opening and the inter-arytenoid cleft position in the laryngeal view, on the success rates of tracheal intubation, and described the repositioning of the Airtraq laryngoscope required to succeed, following a failed tracheal intubation attempt.

Methods

The Ethics Review Board approved this trial and written informed consent was obtained from each patient for

filming and recording of the airway management technique used.

The study was based on a retrospective analysis of videos recorded in the operating theatre during the airway management of elective patients using the Airtraq laryngoscope. The videos were of internal views of the larynx and external recordings. All airway management techniques were performed in anaesthetised patients, who had received neuromuscular blockade, by senior anaesthetists providing anaesthesia for patients in the morbid obesity and gynaecological units.

External films of tracheal intubation were performed by an assistant using a standard video-camera and internal views were automatically recorded using the video-capture system (Vygon, Écouen, France).

All recorded films were converted to a similar 20 images per second format and transferred to a computer for image analysis. External and internal video recordings were synchronised. We then analysed the internal recordings of 50 patients' tracheal intubations requiring greater than one tracheal intubation attempt. For each video and for each tracheal intubation attempt, we selected the image recorded immediately prior to tracheal tube advancement towards the glottic opening. On each image, the outline of the glottic opening and the exact

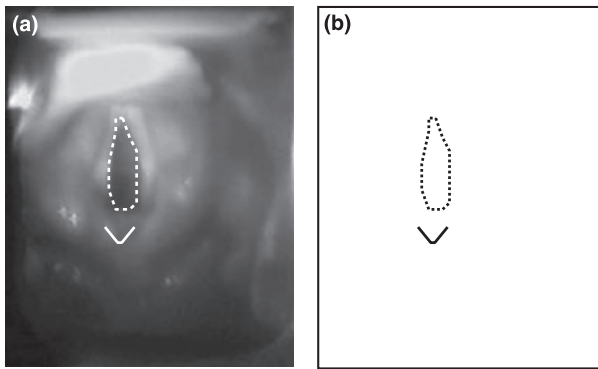


Figure 1 On each image (a) immediately prior to a tracheal intubation attempt, the outlines of the glottic opening and the position of the inter-arytenoids cleft immediately adjacent to posterior glottis were marked (b).

position of the inter-arytenoid cleft immediately adjacent to the posterior glottis were traced and saved (Fig. 1). All traces of successful tracheal intubation and of failed intubation attempts were superimposed to identify the position of the glottic opening and inter-arytenoid cleft in tracheal intubation success and failure respectively. The failed attempts zone (FZ) and the target zone (TZ), were defined as the largest rectangular area, including all glottic opening and inter-arytenoid cleft positions, associated with success or failure of tracheal intubation.

External videos of all the tracheal intubation attempts were then reviewed. Manipulations applied to the Airtraq laryngoscope by the anaesthetist resulting in further success of tracheal attempts were analysed.

Results

The demographic data and tracheal intubation characteristics of 50 obese patients are presented (Table 1). A total

Table 1 Demographic data and tracheal intubation characteristics of the patients.

Demographic data	
Age, years	38 (11)
Gender: male/female, (number of patients)	22/28
Body mass index, kg m ⁻²	41 (9)
Mallampati score, 1–4 (number of patients)	1/16, 2/19, 3/15, 4/0
Thyromental distance, mm	65 (7)
Mouth aperture, mm	33 (4)
Tracheal intubation characteristics	
Duration, s	39 (17)
Percentage of glottic opening visible, %	100
Three tracheal attempts, (number of patients)	5
Four tracheal attempts, (number of patients)	4

of 109 recordings were used for the analysis, this included 59 failures and 50 successes. The failed attempts zone (FZ) and the target zone (TZ) of the glottic opening overlapped. FZ and TZ of the inter-arytenoid cleft did not overlap (Fig. 2). Two efficient techniques were found to be associated with lowering the position of the glottic opening and the inter-arytenoid cleft. The first manoeuvre performed consisted of three movements of the Airtraq laryngoscope tip: downward, backward and upward movements (Fig. 3). Reducing cervical spine extension with in-line head and neck alignment also resulted in lowering the position of the glottic opening and inter-arytenoid cleft in seven non-obese patients.

Discussion

This study has demonstrated that the position of both the glottic opening and the inter-arytenoid cleft affected the success rate of tracheal intubation using the Airtraq laryngoscope. Most successful tracheal intubation attempts occurred when the glottic opening was centrally placed within the view, and the inter-arytenoid cleft was medially located below the horizontal line in the centre of the view. We have also shown that correcting the position of the Airtraq laryngoscope following a failed tracheal intubation attempt, required the anaesthetist to perform a series of standardised manoeuvres.

Improving the factors associated with successful tracheal intubation when using the Airtraq laryngoscope is important for improving the learning process, it is also relevant for daily clinical practice. We found that anaesthetists learning to use the Airtraq laryngoscope, found two manoeuvres were more difficult to master in patients with potentially difficult airways, (i.e. morbidly obese patients). Firstly, placing the Airtraq laryngoscope in the pharynx required significant distal pressure on the tip of the blade to overcome the narrowing at the junction between the oral and pharyngeal spaces. We developed an alternative rotational manoeuvre during pharyngeal insertion of the blade [6] to overcome this problem.

Secondly, although most physicians were able to obtain a view of the glottic opening in all patients (including anticipated difficult airway patients), we found that such optimal laryngeal exposure was not always associated with successful tracheal intubation.

The manipulations required when the glottic opening was not centred in the view were relatively simple to perform. Most anaesthetists intuitively performed small amplitude rotating movements (in the horizontal plane) to the proximal section of the Airtraq laryngoscope to align the axes of the tube emerging from the lateral channel with that of the glottis.

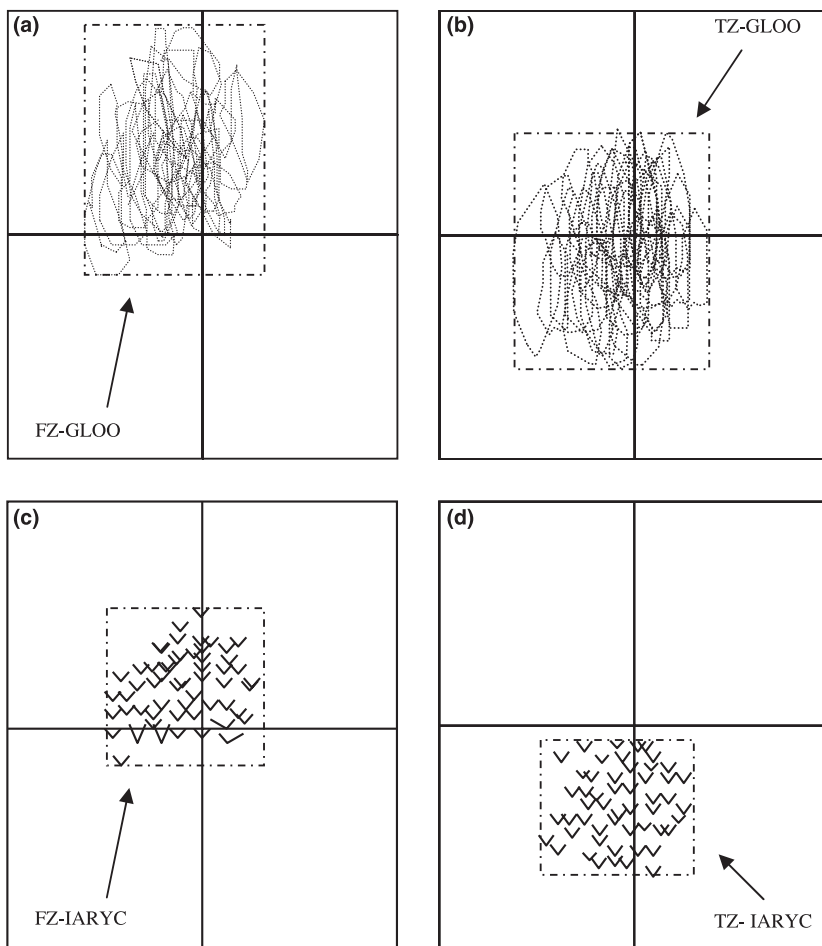


Figure 2 (a–d) Represent schematic illustrations of the marks superimposed for glottic opening (a, b) and for the inter-arytenoid cleft (c, d) positions, just prior to failed (a, c: $n = 59$) and successful (b, d: $n = 50$) tracheal intubation attempts. The failed zone (FZ) and the target zone (TZ) were defined as the largest rectangular area including all glottic opening (GLOO) and inter-arytenoid cleft (IARYC) positions just prior to failed (a, c: $n = 59$) and successful (b, d: $n = 50$) tracheal intubation attempts, respectively. TZ-IARYC TZ-GLOO.

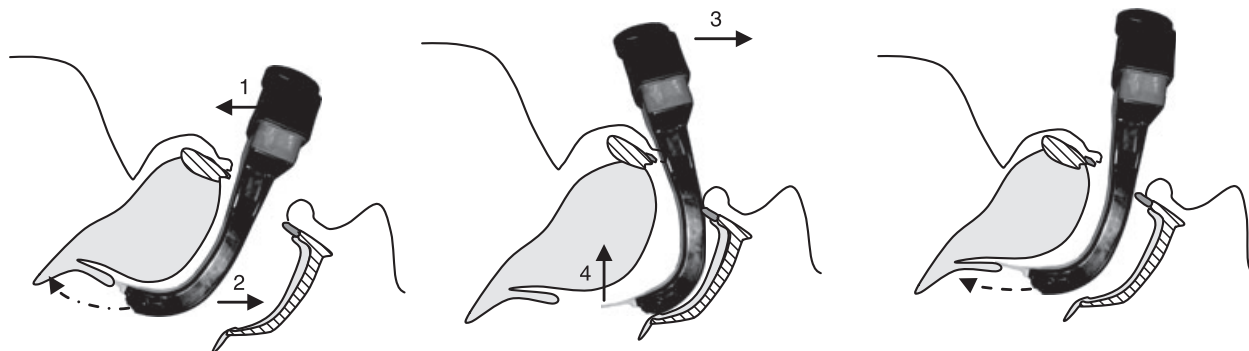


Figure 3 Schematic illustration of the triple manoeuvre: down (1)-back (2)-up (3, 4) applied to the tip of the Airraq laryngoscope blade.

We found that failures of tracheal intubation were almost always associated with an abnormally high position of the glottic opening in the laryngoscopic view, suggesting that the distal tip of the blade was not optimally inserted into the pharynx. However, as we have demonstrated, manipulations to lower the vertical

position of the glottic opening were not routinely used, unless a failure to intubate the trachea occurred. The reasons for attempting tracheal intubation with the glottic opening in a high position in the view will be discussed.

Firstly, we found that tracheal intubation was sometimes possible if the tip of the blade of the Airraq

laryngoscope was positioned below the epiglottis. Indeed, the second attempt at tracheal intubation succeeded in three patients even though the tip of the Airtraq laryngoscope was positioned below the epiglottis and the glottic opening remained relatively highly positioned.

In contrast, similar features resulted in a failure of the second tracheal intubation attempt in four other patients requiring repositioning of the distal tip of the Airtraq laryngoscope blade in the vallecula before the third tracheal intubation attempt was ultimately successful.

In all of the other cases, failure of the first attempt occurred while the epiglottis was visible in the initial view suggesting that the tip of the Airtraq laryngoscope was correctly positioned in the vallecula. For these patients, another parameter, the distance between the glottic opening and the exit of the Airtraq laryngoscope lateral channel, probably affected the success rate of tracheal intubation attempts. The channel design of the Airtraq favours the tracheal tube initially directed downwards [7] before it ascends. A minimal distance between the exit of the Airtraq laryngoscope lateral channel and the glottic opening seems to be important to ensure that the tracheal tube passes over the arytenoids.

In the case of abnormal anatomical features or non optimal Airtraq laryngoscope distal tip position, this distance might be too short resulting in failure of the tracheal intubation attempt. Interestingly, the down-back-up manoeuvre and the reduction of cervical spine extension invariably moved the glottic opening and lowered its position in the laryngoscopic view. Although we did not make measurements on the traces, we believe that these manipulations of the Airtraq laryngoscope and of the patient's neck [8, 9] probably increased the distance between the exit of the Airtraq laryngoscope lateral channel and the glottic opening due to the effect of gravity on the larynx. Of interest in some morbidly obese patients, we could not relate changes in head and neck position to tracheal intubation success rate, but rather to the effect of the down-back-up manoeuvre [10].

By using the down-back-up manoeuvre and the alignment of the head and neck, the glottic opening and the inter-arytenoid cleft position changed from the FZ to the TZ. Although the glottic opening and the inter-arytenoid cleft positions changed significantly following airway manipulations, the position of both anatomical landmarks have different predictive values on the likelihood of success of tracheal intubation.

As seen in Fig. 2, the FZ and the TZ of the glottic opening overlapped vertically, suggesting a poor predictability for success of tracheal intubation. Conversely,

we have demonstrated that the FZ and the TZ of the inter-arytenoid cleft position associated with failure and success of tracheal intubation attempts did not overlap indicating that the inter-arytenoid cleft position is a predictor of tracheal intubation success using the Airtraq laryngoscope. Indeed, when the glottic opening was centred in the view in association with the inter-arytenoid cleft being positioned below the horizontal midline, all tracheal intubation attempts were successful.

In conclusion, we have demonstrated that the inter-arytenoid cleft position is the main factors influencing the likely success of tracheal intubation using the Airtraq laryngoscope.

Acknowledgement

Prodol Ltd Company provided the Airtraq laryngoscopes used in this study.

Financial support

This study was funded by Departmental sources.

Conflict of interest

The authors have no conflict of interest with the Vygon and Prodol Ltd companies.

References

- 1 Maharaj CH, Costello JF, Harte BH, Laffey JG. Evaluation of the Airtraq and Macintosh laryngoscopes in patients at increased risk for difficult tracheal intubation. *Anaesthesia* 2008; **63**: 182–8.
- 2 Woollard M, Mannion W, Lighton D, et al. Use of the Airtraq laryngoscope in a model of difficult intubation by prehospital providers not previously trained in laryngoscopy. *Anaesthesia* 2007; **62**: 1061–5.
- 3 Tong JL. The management of difficult direct laryngoscopy and intubation in a field hospital: an alternative to fiberoptic endoscopy. *Journal of the Royal Army Medical Corps* 2007; **153**: 181–3.
- 4 Woollard M, Lighton D, Mannion W, et al. Airtraq vs standard laryngoscopy by student paramedics and experienced prehospital laryngoscopists managing a model of difficult intubation. *Anaesthesia* 2008; **63**: 26–31.
- 5 Maharaj CH, Higgins BD, Harte BH, Laffey JG. Evaluation of intubation using the Airtraq or Macintosh laryngoscope by anaesthetists in easy and simulated difficult laryngoscopy – a manikin study. *Anaesthesia* 2006; **61**: 469–77.
- 6 Dhonneur G, Ndoko SK, Amathieu R, et al. A comparison of two techniques for inserting the Airtraq laryngoscope in morbidly obese patients. *Anaesthesia* 2007; **62**: 774–7.

- 7 Suzuki A, Abe N, Sasakawa T, Kunisawa T, Takahata O, Iwasaki H. Pentax-AWS (Airway Scope) and Airtraq: big difference between two similar devices. *Journal of Anesthesia* 2008; **22**: 191–2.
- 8 Hirabayashi Y, Fujita A, Seo N, Sugimoto H. A comparison of cervical spine movement during laryngoscopy using the Airtraq or Macintosh laryngoscopes. *Anaesthesia* 2008; **63**: 635–40.
- 9 Hirabayashi Y, Seo N. In-line head and neck position is preferable for tracheal intubation with the Airtraq laryngoscope compared to the sniffing position. *Journal of Anesthesia* 2008; **22**: 189–90.
- 10 Ndoko SK, Amathieu R, Tual L, et al. Tracheal intubation of morbidly obese patients: a randomized trial comparing performance of Macintosh and Airtraq laryngoscopes. *British Journal of Anaesthesia* 2008; **100**: 263–8.