

Lung isolation techniques for patients with difficult airway

Javier H. Campos

Department of Anesthesia, University of Iowa Hospitals and Clinics, Iowa City, Iowa, USA

Correspondence to Dr Javier Campos, MD, Professor of Anesthesia, Vice Chair of Clinical Affairs, Executive Medical Director of Operating Rooms, Director of Cardiothoracic Anesthesia, Department of Anesthesia, University of Iowa Hospitals and Clinics, Iowa City, IA 52242, USA
E-mail: javier-campos@uiowa.edu

Current Opinion in Anaesthesiology
2009, 22:000–000

Purpose of review

One-lung ventilation in the thoracic surgical patient can be achieved with the use of a double-lumen endotracheal tube or an independent bronchial blocker. A number of patients requiring lung isolation have a potentially difficult airway because of previous radiation to the neck or previous surgery to the tongue and larynx. This review will focus on the management of patients who have a difficult airway and require lung isolation.

Recent findings

Identification of the potentially difficult airway during the preoperative evaluation allows the preplanning and selection of the appropriate lung isolation device. Common devices used to achieve one-lung ventilation in patients with difficult airways include independent bronchial blockers (Arndt, Cohen, and Fuji Uniblocker).

Summary

In patients who require one-lung ventilation and who present with a difficult airway, the safest way to establish an airway is by placing a single-lumen endotracheal tube orally or nasotracheally while the patient is awake with the aid of a flexible fiberoptic bronchoscope. Lung isolation in these patients then is achieved by using an independent bronchial blocker; an alternative technique is to use a double-lumen endotracheal tube while using an airway catheter exchange technique. For the patient with a tracheostomy in place, an independent bronchial blocker is recommended.

Keywords

bronchial blockers, difficult airways, double-lumen endotracheal tubes, flexible fiberoptic bronchoscopy, lung separation techniques

Curr Opin Anaesthesiol 22:000–000
© 2009 Wolters Kluwer Health | Lippincott Williams & Wilkins
0952-7907

Introduction

One-lung ventilation (OLV) in the thoracic surgical patient can be achieved with the use of a double-lumen endotracheal tube (DLT) or by bronchial blockade with a wire-guided, endobronchial Arndt blocker, the Cohen Flexitip blocker (Cook Critical Care, Bloomington, Indiana, USA), or the Fuji Uniblocker (Fuji Systems Corporation, Tokyo, Japan) [1].

Patients requiring OLV are identified during the preoperative evaluation to have a potentially difficult airway. Others present with airways that are unexpectedly difficult to intubate after induction of anesthesia. It is estimated that between 5 and 8% of patients with primary lung carcinoma also have a carcinoma of the pharynx, usually in the epiglottic area [2]. Many of these patients have had previous radiation therapy on the neck or previous airway surgery, such as hemimandibulectomy or hemiglossectomy, making intubation and achievement of OLV difficult due to distorted upper airway anatomy. Also, a patient who requires OLV might have distorted anatomy at or beyond the tracheal carina, such as a

descending thoracic aortic aneurysm compressing the entrance of the left mainstem bronchus or an intraluminal or extraluminal tumor near the tracheobronchial bifurcation that makes the insertion of a left-sided DLT relatively difficult or impossible. In this review I will consider the perioperative management of the difficult airway in thoracic surgical patients requiring lung isolation.

Preoperative evaluation of the difficult airway

An airway is termed difficult when conventional laryngoscopy reveals a grade III view (just the epiglottis is seen) or a grade IV view (just part of the soft palate is seen). Once the airway is recognized as being potentially difficult, a careful examination of the patient ensues [3]. Previous anesthesia records should be examined for a history of airway management in the past. Patients should be asked to open their mouths as widely as possible and extend their tongues. The mandibular opening should be assessed and the pharyngeal anatomy observed. The length of the submental space should also be noted. Patients should be evaluated from side to side to assess

any degree of maxillary overbite and their ability to assume the sniffing position. Also, the patency of the nostrils must be assessed in patients who cannot open their mouths, as a nasotracheal approach might be considered. For patients who have a tracheostomy cannula in place, the inlet of the stoma and the circumferential diameter must be assessed when considering replacing the tracheostomy cannula with a specific tube to achieve OLV.

Another group of patients considered to have difficult airways during OLV are those who have distorted anatomy at the entrance of the mainstem bronchus. Such anomalies can be found by reviewing the chest radiographs and by reviewing the computed tomography scans of the chest regarding the mainstem bronchus diameter and anatomy, which can be distorted or compressed. In some instances a flexible fiberoptic bronchoscope will be necessary to assess a distorted area of the airway prior to selection of a specific tube or bronchial blocker to achieve OLV. Table 1 displays the patients at risk of having a difficult intubation during OLV [4].

Securing the airway first: difficult airways and one-lung ventilation

In patients who require OLV and present with the dilemma of a difficult airway, the primary goal – after appropriate airway anesthesia is achieved – is to establish an airway with a single-lumen endotracheal tube placed orally with the aid of a flexible fiberoptic bronchoscope. In selected patients who seem easy to ventilate, this may be performed after induction of anesthesia with a bronchoscope or with a video laryngoscope [5,6]. An alternative when securing the airway prior to placing a lung isolation device is the use of a laryngeal mask airway; with the aid of a flexible fiberoptic bronchoscope, a single-lumen endotracheal tube can be passed through the laryngeal mask airway [7].

Table 1 Patients at risk of having a difficult intubation during one-lung ventilation

Upper airway	Lower airway
Short neck and increased neck circumference	Existing tracheostomy in place
Prominent upper incisors with a receding mandible	Distorted anatomy (trachea/bronchus)
Limited cervical mobility	Compression at the entrance of left mainstem bronchus
Limited jaw opening due to previous surgery	
Radiation therapy of the neck	
Hemiglossectomy/ hemimandibulectomy	
Tumors (mouth, tongue, epiglottis)	

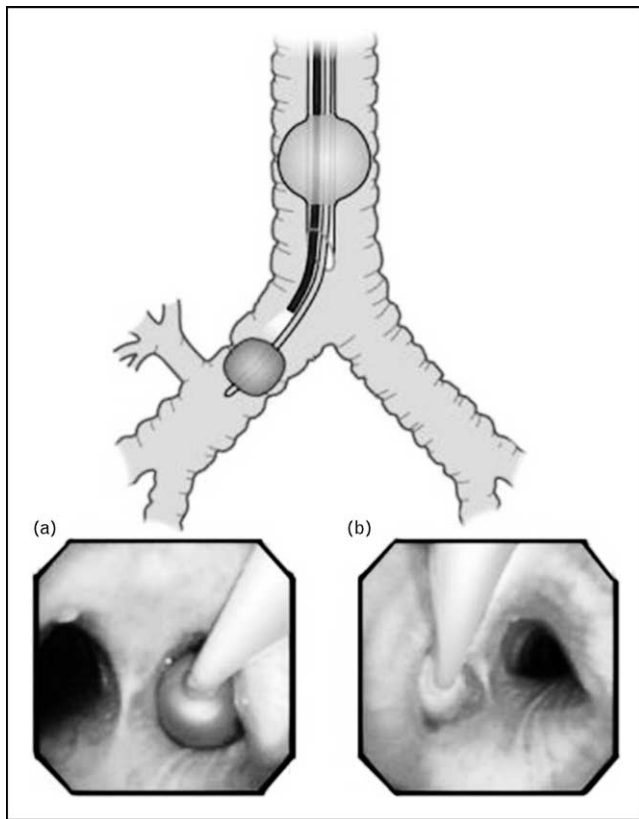
Use of an independent bronchial blocker during lung isolation in patients with difficult airways

In patients who require OLV and present with difficult airways, the first step is to establish an airway with a single-lumen endotracheal tube placed orally while the patient is awake. After topical airway anesthesia is achieved, the single-lumen endotracheal tube is guided with a flexible fiberoptic bronchoscope. The advantage of using a bronchial blocker is that it relies on the use of a single-lumen endotracheal tube for its insertion in the vast majority of cases [8,9]. Common independent bronchial blockers used through a single-lumen endotracheal tube include the following: a wire-guided endobronchial Arndt blocker sized 5.0, 7.0, and 9.0F; the Cohen flexitip blocker size 9.0F; and the Fuji Uniblocker size 4.5 and 9.0F [1,10*].

Also, if the patient requires OLV and cannot be intubated orally, an awake nasotracheal intubation can be performed with a single-lumen endotracheal tube and, once the airway is established, an independent bronchial blocker can be advanced [11,12]. One advantage of one-time intubation with a single-lumen endotracheal tube is that it allows for the conversion to OLV with insertion of an independent bronchial blocker and simple removal of the blocker at the end of a procedure if postoperative ventilatory support is needed [13]. When an independent bronchial blocker is used – specifically size 9.0F – the smallest acceptable single-lumen endotracheal tube size recommended is 8.0mm internal diameter. It is important to have enough space between the bronchial blocker and the flexible fiberoptic bronchoscope so navigation can be achieved within the single-lumen endotracheal tube. Once the single-lumen endotracheal tube is secured in the patient’s trachea, an independent bronchial blocker can be advanced with the aid of a flexible fiberoptic bronchoscope. To achieve OLV the bronchial blocker must be advanced to the bronchus where lung collapse is required. Once the blocker is within the bronchus and the patient is moved into the lateral decubitus position, the endobronchial balloon is inflated. The newest bronchial blockers have high-volume, low-pressure characteristics [14].

The amount of air needed to achieve a complete seal within the bronchus in adults ranges between 5 and 8 ml of air. The optimal position of a bronchial blocker in the left or right bronchus is when the blocker balloon’s outer surface is seen at least 10 mm below the tracheal carina inside the blocked bronchus and a proper seal is achieved. All bronchial blockers should be placed and the optimal position verified with a flexible fiberoptic bronchoscope [15]. Figure 1 shows the optimal position of an independent bronchial blocker through a single-lumen endotracheal tube.

Figure 1 The optimal position of an independent bronchial blocker through a single-lumen endotracheal tube



(a) The bronchial blocker balloon fully inflated into the right mainstem bronchus. (b) Fully inflated balloon in the entrance of the left mainstem bronchus.

Use of laryngeal mask airway and a bronchial blocker

An alternative to achieve OLV in a patient with a difficult airway is with the use of a laryngeal mask airway in conjunction with the use of an independent bronchial blocker. A modified laryngeal mask airway can be made in which the aperture bar of the mask is removed to facilitate passage and insertion of a flexible fiberoptic bronchoscope and an Arndt blocker in a patient with a recent tracheostomy in whom the laryngeal mask airway was placed orally [16]. In addition, the use of a ProSeal laryngeal mask airway has been used with a bronchial blocker in patients in whom the airway was deemed difficult and who required OLV during thoracoscopic surgery [17,18].

Use of a double-lumen endotracheal tube in patients with difficult airways

A different technique to achieve lung isolation is with the use of a DLT. In practice there are three different ways to

place a DLT in a patient with a difficult airway. The first involves the use of airway topical anesthesia and awake fiberoptic bronchoscopy with passage of the flexible fiberoptic bronchoscope through the bronchial lumen of the DLT, where the tube is advanced under bronchoscope guidance [19]. The second technique involves the use of ancillary lighted devices or video laryngoscopes that increase the visualization field of the epiglottis, vocal cords, and passage of the tube. A malleable, lighted stylet (Mercury Medical, Clearwater, Florida, USA) has been reported by using the device within the endobronchial lumen of the DLT, where the tip of the bulb was positioned distally at the tip of the DLT in patients with difficult airways [20]. Others have reported the use of a fiberoptic laryngoscope, the WuScope (Pentax Precision Instruments, Orangeburg, New Jersey, USA) during placement of a DLT in patients with abnormal airway anatomy [21]. One of the advantages of the fiberoptic laryngoscope is that it protects against rupture of the endotracheal cuff during laryngoscopy because the DLT is enclosed with the laryngoscope blade. Disadvantages of this device include the need for smaller sizes of DLTs, such as 35–37F.

The Glidescope video laryngoscope (Saturn Biomedical Systems, Burnaby, British Columbia, Canada) has been used in patients with a difficult airway during placement of a DLT [22]. Another alternative is to intubate the patient's trachea with a single-lumen endotracheal tube during an awake fiberoptic bronchoscopy or after induction of anesthesia, and then a tube exchange technique can be used to replace the existing tube for a DLT after general anesthesia is induced [7]. For a tube exchange catheter to function, it must have a hollow center channel and universal adapters to insufflate oxygen. The exchange catheter must have a flexible tip distally to avoid airway lacerations, be long in length, and have outer markings to control the depth of insertion while in use. For a DLT, the exchange catheter should be at least 83 cm long. The airway Aintree tube exchanger (Cook Critical Care) has a large internal diameter that allows fiberoptic bronchoscopy guidance. Also, a 14F exchange catheter can be used to facilitate insertion of 39 and 41F DLTs. For a 35 or 37F DLT, a single or double airway exchange catheter can be used [4].

The airway exchange catheter, single-lumen endotracheal tube, and the DLT combination should be tested *in vitro* before the exchange. A sniffing position will facilitate tube exchange. After the airway exchange catheter is lubricated, it is advanced through a single-lumen endotracheal tube. The airway catheter should not be inserted deeper than 24 cm from the lips to avoid accidental rupture or laceration of the trachea or bronchi [23].

After cuff deflation, the single-lumen endotracheal tube is withdrawn. Then the endobronchial lumen of the DLT is advanced over the exchange catheter. It is optimal to use a video laryngoscope during the tube exchange to guide the DLT through the glottis under direct vision [5,24]. If a video laryngoscope is not available, then having an assistant perform a standard laryngoscopy during tube exchange partially straightens out the alignment of the oropharynx and glottis and facilitates the exchange. Proper final position of the DLT is then achieved with auscultation and bronchoscopy.

Replacement of a DLT for a single-lumen endotracheal tube can be done at the conclusion of surgery with the use of a double airway exchange catheter. One study using two airway exchange catheters to exchange a DLT for a single-lumen endotracheal tube showed that there was a reduction in the incidence of glottis impingement of the tracheal tube and that there was a higher success rate of passage of the single-lumen endotracheal tube when compared with the use of a single airway exchange catheter [25].

Lung isolation techniques in patients with tracheostomies

A DLT placed through a tracheostomy stoma will be prone to malposition because the upper airway has been shortened and the conventional DLT is too long. Before placing any lung isolation devices through a tracheostomy stoma, it is important to consider whether it is a fresh stoma (i.e. few days old, when the airway can be lost immediately or decannulation can occur) or a chronic tracheostomy. The alternatives to DLT placement to achieve OLV in tracheostomized patients include the

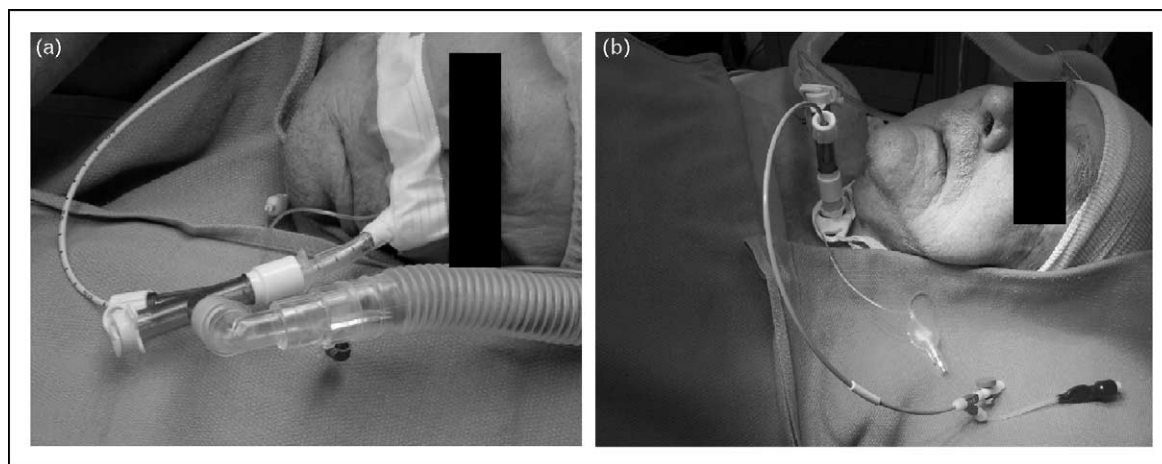
following: insertion of a single-lumen endotracheal tube followed by an independent bronchial blocker [26], the use of a disposable-cuff tracheostomy cannula with an independent bronchial blocker passed coaxially, replacement of the tracheostomy cannula with a specially designed, short DLT (such as the Naruke DLT, which is made for use in tracheostomized patients), placement of a small DLT through the tracheostomy stoma, or, if possible, oral access to the airway for standard placement of a DLT or blocker (this is occasionally an option in patients on prolonged mechanical ventilation for respiratory failure or postoperative complications). Figure 2 shows patients with difficult airways and the use of a bronchial blocker. Figure 3 displays different options to achieve lung isolation in patients who present with difficult airways.

Lung isolation in patients with distorted anatomy of the lower airway

An important group that should be considered when discussing the difficult airway and OLV includes patients who present with lower airway abnormalities, specifically distal trachea or bronchial lesions. The more common problems that will preclude or contraindicate the use of a left-sided DLT include an intraluminal tumor of the left mainstem bronchus or a descending thoracic aortic aneurysm that compresses the entrance of the left mainstem bronchus. One option in these cases is to use a right-sided DLT guided with fiberoptic bronchoscopy [27].

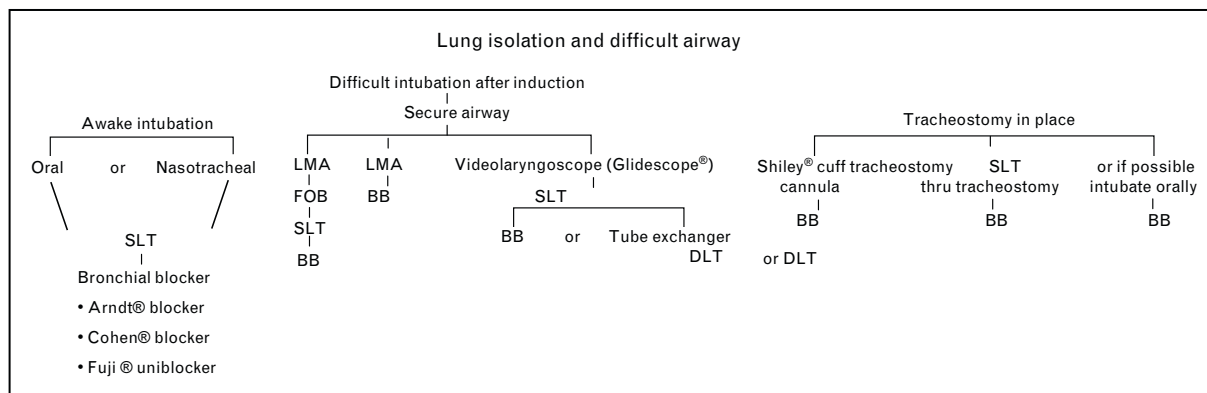
Another group of patients who typically have lower airway abnormalities and require OLV are patients with previous lobectomy; sometimes in these cases the distorted anatomy may contribute to difficulties in recognizing

Figure 2 Use of an Arndt blocker and a Cohen blocker in patients



(a) A patient with a hemimandibulectomy requiring nasotracheal intubation and the use of the Arndt blocker; (b) a patient with a Shiley tracheostomy cannula and the use of a Cohen blocker.

Figure 3 Lung isolation and difficult airway



BB, bronchial blocker; DLT, double-lumen tube; FOB, fiberoptic bronchoscopy; LMA, laryngeal mask airway; SLT, single-lumen tube.

the right and left bronchus because of the loss of an anatomical landmark [28^{*}]. It is important that every anesthesiologist who is involved in placing lung isolation devices is proficient in a complete fiberoptic bronchoscopy examination of the trachea and bronchus in order to achieve 100% success in placement of DLTs and bronchial blockers, particularly in patients with difficult airways [29^{*}].

Conclusion

In patients who require OLV and present with difficult airways, a key element during the preoperative assessment is recognition and identification of the potentially difficult airway. Then the safest way to establish an airway is by securing the airway with a single-lumen endotracheal tube placed orally or nasotracheally with the aid of flexible fiberoptic bronchoscopy. Lung isolation in these patients is achieved best with the use of an independent bronchial blocker. An alternative can be the use of a DLT with an airway catheter exchange technique. For the patient who has a tracheostomy in place, the use of an independent bronchial blocker through a single-lumen endotracheal tube or through a tracheostomy cannula in place is recommended. For all these devices, a flexible fiberoptic bronchoscopy examination is recommended prior, during placement, and at the conclusion of the use of lung isolation devices.

References and recommended reading

Papers of particular interest, published within the annual period of review, have been highlighted as:

- of special interest
- of outstanding interest

Additional references related to this topic can also be found in the Current World Literature section in this issue (pp. 000–000).

- 1 Campos JH. Which device should be considered the best for lung isolation: double-lumen endotracheal tube versus bronchial blockers. *Curr Opin Anaesthesiol* 2007; 20:27–31.
- 2 Hagihira S, Takashina M, Mori T, Yoshiya I. One-lung ventilation in patients with difficult airways. *J Cardiothorac Vasc Anesth* 1998; 12: 186–188.
- 3 Practice guidelines for management of the difficult airway: an updated report by the American Society of Anesthesiologists Task Force on Management of the Difficult Airway. *Anesthesiology* 2003; 98:1269–1277.
- 4 Campos JH. Difficult airway and one-lung ventilation. *Curr Rev Clin Anesth* 2002; 22:199–205.
- 5 Poon KH, Liu EH. The airway scope for difficult double-lumen tube intubation. *J Clin Anesth* 2008; 20:319.
- 6 Davis L, Cook-Sather SD, Schreiner MS. Lighted stylet tracheal intubation: a review. *Anesth Analg* 2000; 90:745–756.
- 7 Perlin DI, Hannallah MS. Double-lumen tube placement in a patient with a difficult airway. *J Cardiothorac Vasc Anesth* 1996; 10:787–788.
- 8 Arndt GA, DeLessio ST, Kranner PW, *et al*. One-lung ventilation when intubation is difficult: presentation of a new endobronchial blocker. *Acta Anaesthesiol Scand* 1999; 43:356–358.
- 9 Cohen E. The Cohen flexitip endobronchial blocker: an alternative to a double lumen tube. *Anesth Analg* 2005; 101:1877–1879.
- 10 Narayanaswamy M, McRae K, Slinger P, *et al*. Choosing a lung isolation device for thoracic surgery: a randomized trial of three bronchial blockers versus double-lumen tubes. *Anesth Analg* 2009; 108:1097–1101.

This is an update on the current use of newer bronchial blockers.

- 11 Campos JH, Kernstine KH. Use of the wire-guided endobronchial blocker for one-lung anesthesia in patients with airway abnormalities. *J Cardiothorac Vasc Anesth* 2003; 17:352–354.
- 12 Angie Ho CY, Chen CY, Yang MW, Liu HP. Use of the Arndt wire-guided endobronchial blocker via nasal for one-lung ventilation in patient with anticipated restricted mouth opening for esophagectomy. *Eur J Cardiothorac Surg* 2005; 28:174–175.
- 13 Cohen E. Pro: The new bronchial blockers are preferable to double-lumen tubes for lung isolation. *J Cardiothorac Vasc Anesth* 2008; 22:920–924.
- 14 Roscoe A, Kanellakos GW, McRae K, Slinger P. Pressures exerted by endobronchial devices. *Anesth Analg* 2007; 104:655–658.
- 15 Campos JH. An update on bronchial blockers during lung separation techniques in adults. *Anesth Analg* 2003; 97:1266–1274.
- 16 Robinson AR III, Gravenstein N, Alomar-Melero E, Peng YG. Lung isolation using a laryngeal mask airway and a bronchial blocker in a patient with a recent tracheostomy. *J Cardiothorac Vasc Anesth* 2008; 22:883–886.
- 17 Ozaki M, Murashima K, Fukutome T. One-lung ventilation using the ProSeal laryngeal mask airway. *Anaesthesia* 2004; 59:726.
- 18 Tsuchihashi T, Ide S, Nakagawa H, *et al*. Differential lung ventilation using laryngeal mask airway and a bronchial blocker tube for a patient with unanticipated difficult intubation. *Masui* 2007; 56:1075–1077.
- 19 Patane PS, Sell BA, Mahla ME. Awake fiberoptic endobronchial intubation. *J Cardiothorac Anesth* 1990; 4:229–231.

6 Thoracic anesthesia

- 20 O'Connor CJ, O'Connor TA. Use of lighted stylets to facilitate insertion of double-lumen endobronchial tubes in patients with difficult airway anatomy. *J Clin Anesth* 2006; 18:616–619.
- 21 Smith CE, Kareti M. Fiberoptic laryngoscopy (WuScope) for double-lumen endobronchial tube placement in two difficult-intubation patients. *Anesthesiology* 2000; 93:906–907.
- 22 Hernandez AA, Wong DH. Using a glidescope for intubation with a double lumen endotracheal tube. *Can J Anaesth* 2005; 52:658–659.
- 23 Thomas V, Neustein SM. Tracheal laceration after the use of an airway exchange catheter for double-lumen tube placement. *J Cardiothorac Vasc Anesth* 2007; 21:718–719.
- 24 Chen A, Lai HY, Lin PC, *et al.* Glidescope-assisted double-lumen endobronchial tube placement in a patient with an unanticipated difficult airway. *J Cardiothorac Vasc Anesth* 2008; 22:170–172.
- 25 Suzuki A, Uraoka M, Kimura K, Sato S. Effects of using two airway exchange catheters on laryngeal passage during change from a double-lumen tracheal tube to a single-lumen tracheal tube. *Br J Anaesth* 2007; 99:440–443.
- 26 Tobias JD. Variations on one-lung ventilation. *J Clin Anesth* 2001; 13:35–39.
- 27 Campos JH. Progress in lung separation. *Thorac Surg Clin* 2005; 15:71–83.
- 28 Campos JH. Update on selective lobar blockade during pulmonary resections.
• *Curr Opin Anaesthesiol* 2009; 22:18–22.
This article addresses the issue of recognition of tracheobronchial anatomy with the fiberscope in cases with previous lobectomy.
- 29 Campos JH. Update on tracheobronchial anatomy and flexible fiberoptic bronchoscopy in thoracic anesthesia. *Curr Opin Anaesthesiol* 2009; 22:4–10.
The article is an update on airway anatomy and use of flexible fiberoptic bronchoscopy during placement of lung isolation devices.